

Robert A. Gross, MD, PhD, FAAN, Editor-in-Chief, *Neurology*[®]



Notable in *Neurology* this week

This issue features an article that investigates the use of interictal high-frequency oscillations in epilepsy surgery for predication of postsurgical seizure outcome; another determines the safety and efficacy of IV thrombolysis in patients with acute ischemic stroke and a history of dual antiplatelet therapy pretreatment. A featured Contemporary Issues article examines the methodology behind the quantification of physician-scientists in the discussion of funding efforts aimed at the attrition of the physician-scientist workforce.

Articles

Retinal thinning associates with nigral dopaminergic loss in de novo Parkinson disease

Retinal anatomical changes may be a Parkinson disease (PD) biomarker due to correlation with clinical staging of PD and dopaminergic degeneration within the brain. Correlation between inner retinal layer thinning and dopamine transporter loss in the substantia nigra increases the possibility of pathologic interconnection between the retina and nigral dopaminergic cell degeneration in PD.

Page 497

From editorialists Adams & La Morgia: "Ultimately, if retinal thinning is pathologically linked to nigral dopaminergic loss, retinal imaging could be used for making an early diagnosis, monitoring of disease progression, and measuring efficacy of neuroprotective therapies in PD."

Page 493

Deep brain stimulation improves restless legs syndrome in patients with Parkinson disease

Restless legs syndrome (RLS) is relatively common among patients with Parkinson disease. The authors studied the effect of subthalamic nucleus deep brain stimulation on patients with Parkinson disease and RLS. Subthalamic nucleus deep brain stimulation decreased symptoms of RLS and was sustained over a 2-year period.

Page 498

Unintended pregnancy, prenatal care, newborn outcomes, and breastfeeding in women with epilepsy

In this study, over half of pregnancies in women with epilepsy were unintended. Treating physicians must prescribe appropriate antiepileptic drugs and emphasize folic acid in all women with epilepsy of childbearing potential. Further work is needed to educate women with epilepsy about the use of folic acid, the importance of planning pregnancy, and the safety of breastfeeding.

Page 500

MORE ONLINE

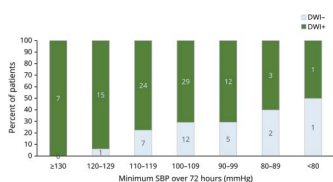
🎧 Editor's Summary

Audio summary of highlighted articles.

NPub.org/edsum

Continued

Cerebral ischemia and deterioration with lower blood pressure target in intracerebral hemorrhage



After an institutional protocol change in the systolic blood pressure target, the authors sought the incidence and predictors of acute cerebral ischemia and neurologic deterioration in patients with intracerebral hemorrhage. Intensive lowering of systolic blood pressure, particularly <120 mm Hg, was associated with increased remote cerebral ischemic lesions and acute neurologic deterioration.

Page 503

From editorialists Kapinos & Hanley: “The authors demonstrate that ischemia is not due to confounding factors (embolisms, hypoperfusion from carotid stenosis, or spontaneous occlusive microangiopathic events) or local compression from the hematoma. The dose–effect relationship provides compelling evidence of graded hypoperfusion injury and that <130 mm Hg is probably too low.”

Page 495

NB: “Education Research: A framework for global health curricula for neurology trainees,” p. 528. To check out other Resident & Fellow Section Education Research articles, point your browser to Neurology.org/N and click on the link to the Resident & Fellow Section. At the end of the issue, check out the Video NeuroImage showing a case of alien hand syndrome in a 94-year-old patient. This week also includes a Medical Hypothesis titled “Idiopathic intracranial hypertension: The veno lymphatic connections.”

NEW EPISODE



September 11, 2018

CME Opportunity:

Listen to this week’s *Neurology* Podcast and earn 0.5 AMA PRA Category 1 CME Credits™ by answering the multiple-choice questions in the online Podcast quiz.

Dual antiplatelet therapy pretreatment in intravenous thrombolysis for acute ischemic stroke (see p. 504)

1. Featured Article: Dual antiplatelet therapy pretreatment in intravenous thrombolysis for acute ischemic stroke
2. What’s Trending: Recurrent glioblastoma treated with recombinant poliovirus

Dr. Andy Southerland talks with Dr. Andrei Alexandrov about his paper on dual antiplatelet therapy pretreatment for acute ischemic stroke. In the second part of the podcast, Dr. Kait Nevel focuses her interview with Dr. Darrell Bigner on treatment for recurrent glioblastoma.

Disclosures can be found at Neurology.org.

Neurology®

Spotlight on the September 11 issue

Robert A. Gross

Neurology 2018;91;491-492

DOI 10.1212/WNL.0000000000006175

This information is current as of September 10, 2018

Updated Information & Services

including high resolution figures, can be found at:
<http://n.neurology.org/content/91/11/491.full>

Permissions & Licensing

Information about reproducing this article in parts (figures, tables) or in its entirety can be found online at:
http://www.neurology.org/about/about_the_journal#permissions

Reprints

Information about ordering reprints can be found online:
<http://n.neurology.org/subscribers/advertise>

Neurology® is the official journal of the American Academy of Neurology. Published continuously since 1951, it is now a weekly with 48 issues per year. Copyright © 2018 American Academy of Neurology. All rights reserved. Print ISSN: 0028-3878. Online ISSN: 1526-632X.

