

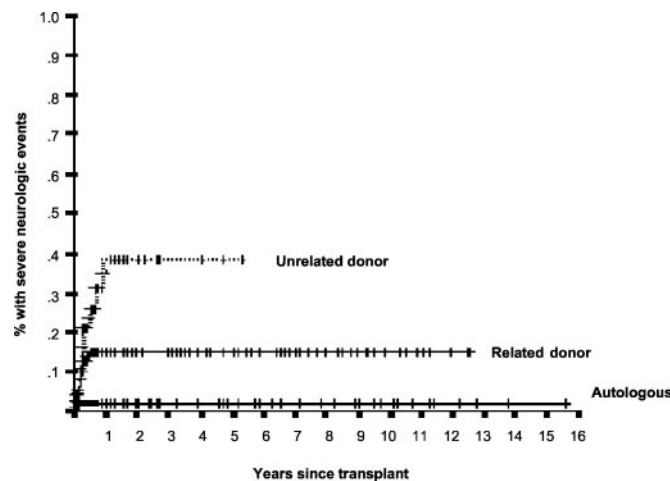
References

1. Takahashi N, Kawamura M, Araki S. Isolated hand palsy due to cortical infarction: localization of the motor hand area. *Neurology* 2002;58:1412–1414.
2. Terao Y, Hayashi H, Kanda T, Tanabe H. Discrete cortical infarction with prominent impairment of thumb flexion. *Stroke* 1993;24:2118–2120.
3. Yoneda Y, Mori E, Tabuchi M, Yamadori A. Pure motor monoparesis due to intracerebral hemorrhage. *Stroke* 1993;24:142–143.
4. Hochman MS, DePrima SJ. Early diagnosis by diffusion weighted MRI of pure motor stroke limited to finger weakness. *J Neuroimaging* 1998;8:179–181.
5. Lee PH, Han SW, Heo JH. Isolated weakness of the fingers in cortical infarction. *Neurology* 1998;50:823–824.
6. Phan TG, Evans BA, Huston J. Pseudounilateral palsy from a small infarct of the precentral knob. *Neurology* 2000;54:2185–2186.

Corrections

Severe neurologic complications after hematopoietic stem cell transplantation in children

In the article, “Severe neurologic complications after hematopoietic stem cell transplantation in children” (*Neurology* 2002;59:1895–1904) by Faraci et al., the curve regarding “Unrelated donor” recipients was incorrect. The author apologizes for this error. The correct figure is printed below:



Use of *Ephedra*-containing products and risk for hemorrhagic stroke

In the article, “Use of *Ephedra*-containing products and risk for hemorrhagic stroke” (*Neurology* 2003;60:132–135) by Morgenstern et al., the author R.I. Horwitz should have been listed as an MD.

Neurology[®]

Use of *Ephedra*-containing products and risk for hemorrhagic stroke

Neurology 2003;60;1055
DOI 10.1212/WNL.60.6.1055-a

This information is current as of March 25, 2003

Updated Information & Services

including high resolution figures, can be found at:
<http://n.neurology.org/content/60/6/1055.2.full>

Permissions & Licensing

Information about reproducing this article in parts (figures, tables) or in its entirety can be found online at:
http://www.neurology.org/about/about_the_journal#permissions

Reprints

Information about ordering reprints can be found online:
<http://n.neurology.org/subscribers/advertise>

Neurology® is the official journal of the American Academy of Neurology. Published continuously since 1951, it is now a weekly with 48 issues per year. Copyright . All rights reserved. Print ISSN: 0028-3878. Online ISSN: 1526-632X.

