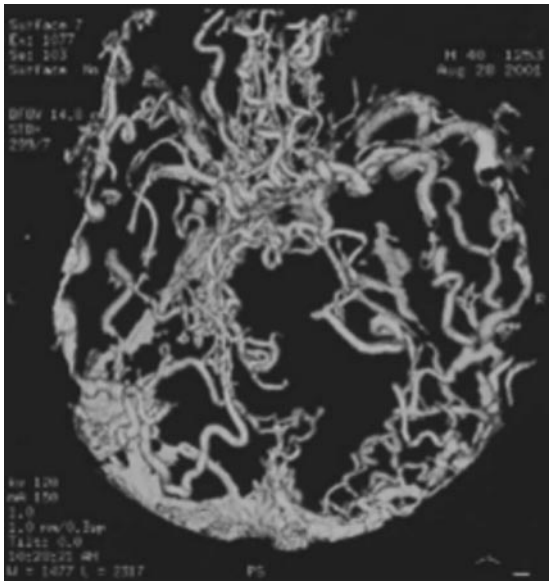

Figure 1. CT angiography showing direct communication of middle meningeal branches with the dural veins with no nidus.

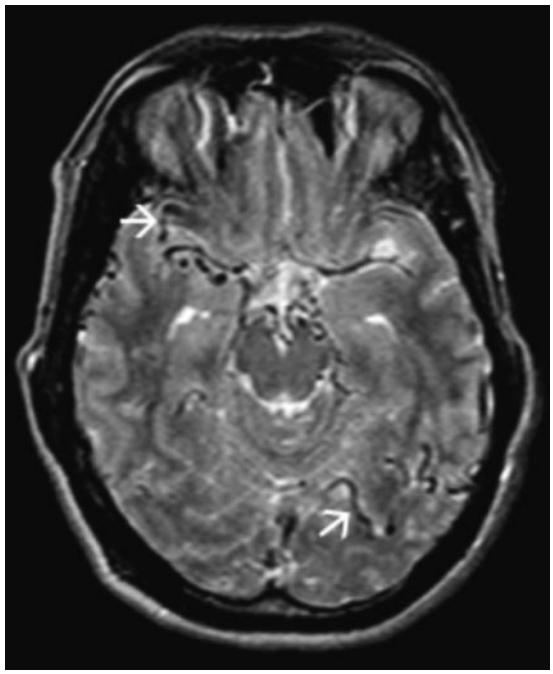

Figure 2. T2-weighted axial MRI of the brain showing direct communication of one branch of the middle meningeal artery with dural vein. Prominent vessels are seen in the region of the left occipital lobe and ambient cistern.

"Spaghetti in brain": DAVF

Mathew Alexander, DM; Prakash Balasubramaniam, MD; and Sunithi Elizabeth Mani, MBBS Vellore, India

A man aged 45 years sought treatment for a 5-year history of chronic headache that had worsened in the past month. There was no history of blurring of vision, diplopia, or vomiting. Physical examination revealed bilateral papilledema. There were no bruits or lateralizing or meningeal signs. CT brain scan showed bilateral small frontoparietal subdural hematoma, and CT angiography (figure 1) revealed typical "spaghetti" appearance of multiple intracranial dural arteriovenous fistulae.[1] T2-weighted MRI of the brain (figure 2) revealed dural fistulae, and MR angiography confirmed the findings with no evidence of dural sinus thrombosis.[2] In extensive fistulae, no definitive intervention was possible. The patient subsequently developed a subarachnoid hemorrhage and succumbed to the bleed.

Address correspondence and reprint requests to Dr. Mathew Alexander, Department of Neurological Sciences, Christian Medical College and Hospital, Vellore 63204, India; e-mail: mathew_koleth@hotmail.com

1. Dietrich U, Wanke I, Asgari S, Forsting M, Oppel F. Dural arteriovenous fistulas with intracranial hemorrhage: diagnostic and therapeutic aspects. Zentralbl Neurochir 2003;64:12–18.
2. Coley SC, Romanowski CA, Hodgson TJ, Griffith PD. Dural arteriovenous fistulae: noninvasive diagnosis with dynamic MR digital subtraction angiography. AJNR Am J Neuroradiol 2002;23:404–407.

 Copyright © 2004 by AAN Enterprises, Inc.

Copyright © by AAN Enterprises, Inc. Unauthorized reproduction of this article is prohibited.

Neurology®

"Spaghetti in brain": DAVF

Mathew Alexander, Prakash Balasubramaniam and Sunithi Elizabeth Mani

Neurology 2004;63;892
DOI 10.1212/01.WNL.0000130336.97388.7E

This information is current as of September 13, 2004

Updated Information & Services	including high resolution figures, can be found at: http://n.neurology.org/content/63/5/892.full
References	This article cites 2 articles, 0 of which you can access for free at: http://n.neurology.org/content/63/5/892.full#ref-list-1
Permissions & Licensing	Information about reproducing this article in parts (figures,tables) or in its entirety can be found online at: http://www.neurology.org/about/about_the_journal#permissions
Reprints	Information about ordering reprints can be found online: http://n.neurology.org/subscribers/advertise

Neurology ® is the official journal of the American Academy of Neurology. Published continuously since 1951, it is now a weekly with 48 issues per year. Copyright . All rights reserved. Print ISSN: 0028-3878. Online ISSN: 1526-632X.

AMERICAN ACADEMY OF NEUROLOGY®