

Clinical Reasoning: Blurred vision and dancing feet

Restless legs syndrome presenting in mitochondrial disease

H. Aitken
G. Gorman, MRCP
R. McFarland,
MRCPCH
M. Roberts, FRCP
R.W. Taylor, FRCPat
D.M. Turnbull, FRCP

Address correspondence and
reprint requests to Professor D.M.
Turnbull, Mitochondrial
Research Group, 4th Floor, The
Medical School, Newcastle
University, Newcastle upon Tyne,
NE2 4HH, UK
d.m.turnbull@ncl.ac.uk

SECTION 1

A 58-year-old woman presented to a neuro-ophthalmologist with a 5-year history of progressively blurred vision, diplopia, and longstanding bilateral ptosis. She described occasional choking episodes after eating as well as fatigue and shortness of breath after minimal exertion. Her older sibling had received corrective eyelid surgery for ptosis and two nieces had ptosis and proximal myopathy and were being investigated in another center.

Direct and consensual pupillary light reflexes were normal with no rapid alternating pupillary defect.

Visual acuity was 20/20 on the right and 20/30 on the left. She had bilateral symmetric ptosis obscuring two-thirds of the pupil and restriction of eye movements below 60% of normal in all directions of gaze. Lower limb examination revealed symmetric proximal limb weakness (Medical Research Council grade 4+) with reduced reflexes and flexor plantars. Tandem gait was hesitant.

Questions for consideration:

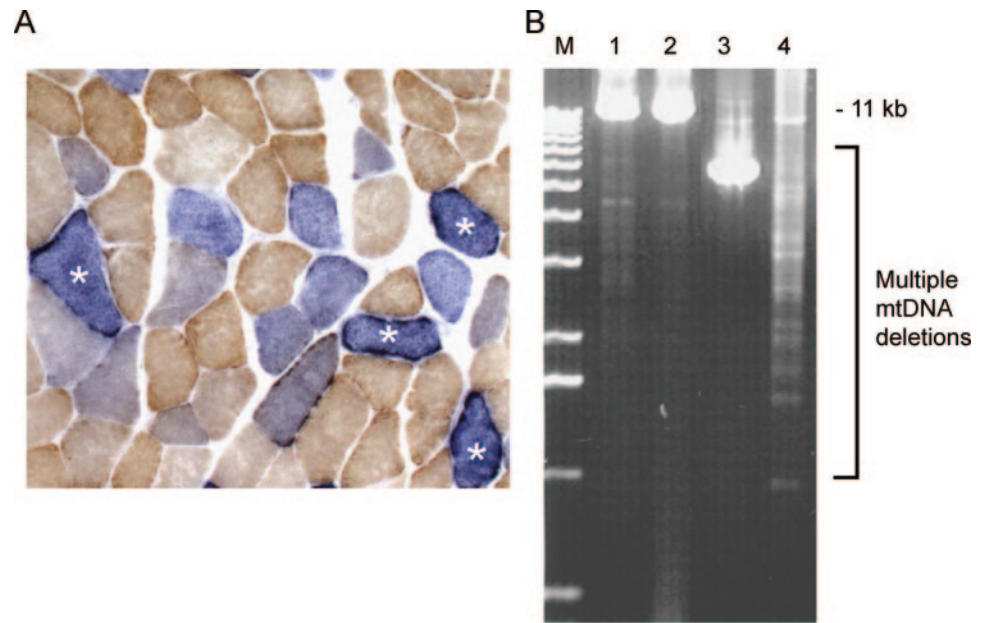
1. What are the possible diagnoses?
2. What initial investigations would you recommend?

[GO TO SECTION 2](#)

From Mitochondrial Research Group (H.A., G.G., R.M., R.W.T., D.M.T.), The Medical School, Newcastle University, Newcastle upon Tyne; and Department of Neurology (M.R.), Hope Hospital, Salford, UK.

Disclosure: The authors report no disclosures.

Figure 1 Histochemical and mitochondrial genetic investigations in patient muscle



(A) Sequential cytochrome c oxidase (COX)/succinate dehydrogenase (SDH) histochemistry in the muscle biopsy from our patient reveals significant numbers (13%) of COX-deficient fibers, some of which show clear subsarcolemmal accumulation of abnormal mitochondria (marked with an asterisk). (B) Long-range PCR clearly demonstrates the presence of multiple mitochondrial DNA (mtDNA) deletions in patient muscle DNA (lane 4) compared to muscle DNA extracted from two age-matched controls (lanes 1 and 2); lane 3 shows muscle DNA amplified from a patient with a single large-scale mtDNA deletion for comparison. M = size marker.

SECTION 2

The initial differential diagnosis included Graves thyroid eye disease, a neuromuscular junction disorder (myasthenia gravis or botulism), oculopharyngeal muscular dystrophy, Miller Fisher variant of Guillain-Barré syndrome, and progressive muscular dystrophy.

Free thyroxin and thyroid stimulating hormone levels were normal. Thyroid antibodies were negative. Acetylcholine receptor antibody assay was negative and repetitive nerve stimulation to exclude a neuromuscular junction disorder was normal. Electromyography of proximal upper limb muscles revealed an increased number of short duration motor units consistent with borderline myopathy. Nerve conduction velocities were normal, reducing the likelihood of an immune-mediated inflammatory neuropathy.

Due to the chronicity of symptoms, presence of gaze paresis, myopathic findings on neurophysiologic assessment, and family history of ocular complications suggestive of dominant inheritance, a muscle biopsy was performed. Polyadenylate binding-

protein nuclear 1 (*PABPN1*) gene mutation analysis to exclude oculopharyngeal muscular dystrophy was deferred pending muscle biopsy analysis.

The muscle biopsy showed 13% cytochrome *c* oxidase (COX)-deficient fibers, significant numbers of ragged red fibers but no excess of lipid or glycogen accumulation, and subsarcolemmal accumulation of abnormal mitochondria suggestive of a mitochondrial cytopathy (figure 1A). Testing for common mitochondrial DNA (mtDNA) point mutations (MELAS m.3243A>G [mitochondrial encephalopathy, lactic acidosis and stroke-like episodes], MERRF m.8344A>G [myoclonic epilepsy with ragged red fibers], and NARP m.8993T>G/C [neuropathy, ataxia, and retinitis pigmentosa]) did not reveal any abnormalities. Long-range PCR, however, revealed multiple mtDNA deletions in muscle (figure 1B).

Questions for consideration:

1. What is your differential diagnosis at this point?
2. What additional diagnostic tests would you consider at this time?

GO TO SECTION 3

SECTION 3

Due to the presence of multiple mtDNA deletions indicative of an mtDNA maintenance defect, polymerase γ (*POLG1*) gene amplification and sequencing was performed. This detected two previously described heterozygous mutations in compound p.T251I and p.P587L, frequently found in *cis* and subsequently confirmed as showing an autosomal dominant pattern of inheritance. No mutations were identified in the *PEO1* (Twinkle) and *SLC25A4* (ANT1) genes.

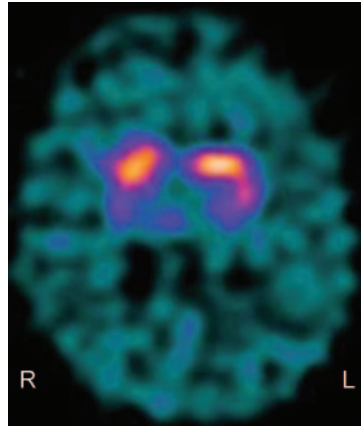
The patient presented 10 months later with an unpleasant “jumping” sensation in her feet when at rest which was relieved by movement. Symptoms were worse at night and she also described sudden involuntary movements of her lower limbs. These symptoms did not subjectively impact on sleep hygiene. Family history was negative for these symptoms.

Questions for consideration:

1. What condition is this patient describing?
2. What additional tests would you consider at this time?

GO TO SECTION 4

Figure 2 Dopamine transporter scan showing asymmetric uptake of tracer in the putamen with relative reduced uptake in the right putamen compared to the left side, consistent with impairment of the dopamine transporter mechanism



SECTION 4

This patient's symptoms were consistent with restless legs syndrome (RLS) and periodic limb movements of sleep. Medications included ubiquinone only. Initial blood tests including full blood count, iron, ferritin, glucose, renal and liver profiles, thyroid function tests, and vitamin B12 levels were normal. Nerve conduction studies were normal excluding a peripheral neuropathy. Due to the risks associated with developing a dopamine deficient syndrome with *POLG* mutations, 123-I Ioflupane DatSCAN imaging was performed.

This showed asymmetric uptake of tracer in the putamen with relative reduced uptake in the right putamen compared to the left side (figure 2) consistent with impairment of the dopamine transporter mechanism suggestive of parkinsonism. She declined pharmacologic intervention for symptom control. The results of *POLG1* gene analysis in the affected relatives revealed the same heterozygous mutations.

DISCUSSION Mutations of the *POLG1* gene are thought to account for up to 25% of adult mitochondrial disease presentations.¹ This patient presented with gaze paresis, multiple mtDNA deletions in skeletal muscle, and a family history of ptosis. It is widely accepted that this constellation of factors warrants consideration of *POLG1* as a possible diagnosis.¹ Autosomal dominant progressive external ophthalmoplegia (adPEO) caused by a mutation in *POLG1* was first described in 2001.² Pathogenic mutations in the genes encoding *POLG*, the enzyme that synthesizes mitochondrial DNA, have been described in patients with dominant, recessive, and

sporadic PEO, as well as in patients presenting with parkinsonism, neuropathy, late onset ataxia, and Alpers syndrome.³ Mitochondrial dysfunction has been linked to Parkinson disease (PD) with mtDNA deletions and rearrangements found in the substantia nigra of patients with PD and individuals with *POLG* mutations.^{4,5}

RLS is a common yet underdiagnosed condition with multiple causes.⁶ Secondary causes excluded in this patient include iron deficiency, pregnancy, and end-stage renal failure.⁷ The patient fulfilled the essential criteria for RLS: the urge to move the legs which is initiated or worsened by inactivity, relieved by movement and worse at night.^{6,8} High prevalence of RLS is reported in this patient's age group and gender (women, aged 50–59 years).⁹ Associated features are a family history of RLS, a positive therapeutic response to dopaminergic drugs, periodic limb movements in sleep, and sleep disturbance.⁶

Pathophysiologic concepts for RLS include dysfunction of the dopaminergic system based on clinical observation and response to dopamine and dopamine agonists. RLS symptoms may be prevalent in PD; however, an etiologic link has not been shown. Unlike PD, RLS is not a degenerative disorder and there is little evidence of degeneration of dopaminergic neurons, although neuroimaging shows a subtle functional impairment of the dopaminergic system with reduced dopamine binding in the caudate and putamen.¹⁰ Although extrapyramidal features have been described in *POLG1* mutations, moreover, an association with RLS has yet to be reported.

The patient we describe has an unusual presentation of a commonly occurring syndrome, RLS, and extends the ever-evolving spectrum of clinical phenotypes attributable to mutation of the *POLG1* gene.

REFERENCES

1. Chinnery PF, Zeviani M. 155th ENMC workshop: polymerase gamma disorders of mitochondrial DNA synthesis. *Neuromuscul Disord* 2008;18:259–267.
2. Van Goethem G, Dermaut B, Lofgren A, et al. Mutation of *POLG* is associated with progressive external ophthalmoplegia characterized by mtDNA deletions. *Nat Genet* 2001;28:211–212.
3. Horvath R, Hudson G, Ferrari G. Phenotypic spectrum associated with mutations of the mitochondrial polymerase gamma gene. *Brain* 2006;129:1674–1684.
4. Guangyu G, Reyes P, Golden G, et al. Mitochondrial DNA deletions/rearrangements in Parkinson disease and related neurodegenerative disorders. *J Neuropathol Exp Neurol* 2002;61:634–639.
5. Mosley RL, Benner EJ, Kadiu I. Neuroinflammation, oxidative stress and the pathogenesis of Parkinson's disease. *Clin Neurosci Res* 2006;6:261–281.

6. Allen RP, Picchiatti D, Hening WA, et al. Restless legs syndrome: diagnostic criteria, special considerations, and epidemiology: a report from the restless legs syndrome diagnosis and epidemiology workshop at the National Institutes of Health. *Sleep Med* 2003;4:101–119.
7. Allen RP. Controversies and challenges in defining the etiology and pathophysiology of restless legs syndrome. *Am J Med* 2007;120:13–21.
8. Walters AS. Toward a better definition of the restless legs syndrome: the International Restless Legs Syndrome Study Group. *Mov Disord* 1995;10:634–642.
9. Hogl B, Kiechl S, Willeit J, et al. Restless legs syndrome: a community-based study of prevalence, severity, and risk factors. *Neurology* 2005;64:1920–1924.
10. Tan E-K. Restless legs syndrome and Parkinson's disease: is there an etiologic link? *J Neurol* 2006;253:33–37.

Neurology[®]

Clinical Reasoning: Blurred vision and dancing feet: Restless legs syndrome presenting in mitochondrial disease

H. Aitken, G. Gorman, R. McFarland, et al.

Neurology 2009;72:e86-e90

DOI 10.1212/WNL.0b013e3181a411b8

This information is current as of May 4, 2009

Updated Information & Services	including high resolution figures, can be found at: http://n.neurology.org/content/72/18/e86.full
References	This article cites 10 articles, 1 of which you can access for free at: http://n.neurology.org/content/72/18/e86.full#ref-list-1
Subspecialty Collections	This article, along with others on similar topics, appears in the following collection(s): All Movement Disorders http://n.neurology.org/cgi/collection/all_movement_disorders Eyelids http://n.neurology.org/cgi/collection/eyelids Mitochondrial disorders http://n.neurology.org/cgi/collection/mitochondrial_disorders Ocular motility http://n.neurology.org/cgi/collection/ocular_motility
Permissions & Licensing	Information about reproducing this article in parts (figures, tables) or in its entirety can be found online at: http://www.neurology.org/about/about_the_journal#permissions
Reprints	Information about ordering reprints can be found online: http://n.neurology.org/subscribers/advertise

Neurology® is the official journal of the American Academy of Neurology. Published continuously since 1951, it is now a weekly with 48 issues per year. Copyright . All rights reserved. Print ISSN: 0028-3878. Online ISSN: 1526-632X.

