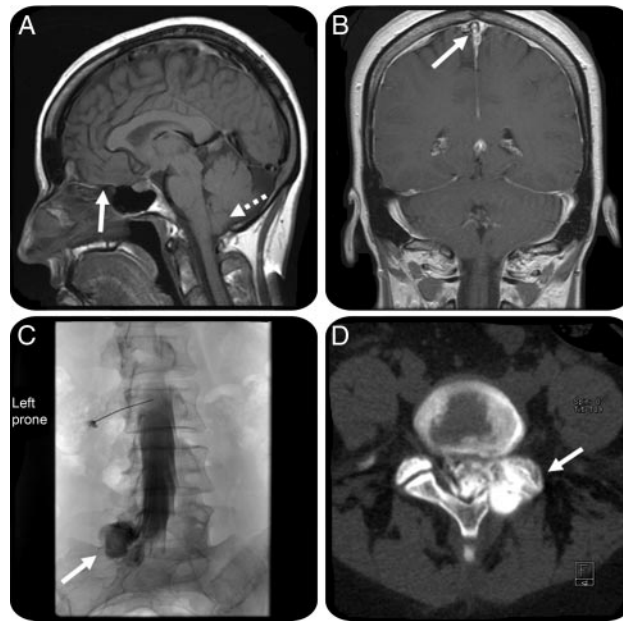


# An unexpected cause of orthostatic headache

## Delayed postlaminectomy pseudomeningocele

**Figure** Head MRI with changes of intracranial hypotension and myelogram showing delayed onset pseudomeningocele at the postoperative site



(A) Low-lying cerebellar tonsils (dashed arrow) and orbitofrontal compression over sphenoid sinus (arrow). (B) Mild diffuse dural enhancement overlying both cerebral hemispheres and sagittal venous sinus dilatation (arrow). (C) Active contrast extravasation into a large 4 cm × 2.4 cm × 2.9 cm pseudomeningocele from (D) the left L5-S1 hemilaminectomy defect (indicated by arrows).

A 41-year-old woman underwent a left L5-S1 hemilaminectomy 7 months prior to the onset of an acute postural headache. MRI brain revealed intracranial hypotension. Two empiric blood patches were unsuccessful. CT myelogram showed a large pseudomeningocele at the surgical site not noted on MRI lumbar spine obtained 2 months postoperatively. Facet instability post-mesial facetectomy likely caused a dural tear on resumption of normal activity. The headache resolved after pseudomeningocele closure. Postoperative pseudomeningocele formation is well-recognized,<sup>1</sup> but acute orthostatic headache from delayed pseudomeningocele formation at a spinal surgical site has been only once previously described<sup>2</sup> and should be considered.

*Gabriele C. De Luca, MD, PhD, Ivan Garza, MD, Giuseppe Lanzino, MD, James C. Watson, MD, Rochester, MN*

*Disclosure:* Dr. De Luca reports no disclosures. Dr. Garza serves and receives compensation as Headache Section Editor for *Current Neurology and Neuroscience Reports* and as an author for publications in *UpToDate* and has received speaker honoraria from the American Headache Society. Dr. Lanzino serves on a scientific advisory board for Actelion Pharmaceuticals Ltd.; serves on the editorial board of the *Journal of Neurosurgery* and *Neurocritical Care*; receives royalties from the publication of *Cavernous Malformations of the Brain and Spinal Cord* (Thieme, 2008); has received speaker honoraria from Synthes Inc.; and has received research support from eV3 (educational grant). Dr. Watson reports no disclosures.

*Address correspondence and reprint requests to Dr. James C. Watson, Mayo Clinic College of Medicine, Mayo Building, 8th floor, 200 First Street SW, Rochester, MN 55905; watson.james@mayo.edu*

### REFERENCES

1. Beier AD, Soo TM, Claybrooks R. Subdural hematoma after microdiscectomy: a case report and review of the literature. *Spine J* 2009;9:e9–e12.
2. Marlin AE, Epstein F, Rovit R. Positional headache and syncope associated with a pseudomeningocele. *Arch Neurol* 1980;37:736–737.

# Neurology<sup>®</sup>

## **An unexpected cause of orthostatic headache: Delayed postlaminectomy pseudomeningocele**

Gabriele C. De Luca, Ivan Garza, Giuseppe Lanzino, et al.

*Neurology* 2010;74;1553

DOI 10.1212/WNL.0b013e3181dd4319

**This information is current as of May 10, 2010**

<b>Updated Information &amp; Services</b>	including high resolution figures, can be found at: <a href="http://n.neurology.org/content/74/19/1553.full">http://n.neurology.org/content/74/19/1553.full</a>
<b>References</b>	This article cites 2 articles, 0 of which you can access for free at: <a href="http://n.neurology.org/content/74/19/1553.full#ref-list-1">http://n.neurology.org/content/74/19/1553.full#ref-list-1</a>
<b>Subspecialty Collections</b>	This article, along with others on similar topics, appears in the following collection(s): <b>All Imaging</b> <a href="http://n.neurology.org/cgi/collection/all_imaging">http://n.neurology.org/cgi/collection/all_imaging</a> <b>Disc disease</b> <a href="http://n.neurology.org/cgi/collection/disc_disease">http://n.neurology.org/cgi/collection/disc_disease</a> <b>Low pressure syndrome</b> <a href="http://n.neurology.org/cgi/collection/low_pressure_syndrome">http://n.neurology.org/cgi/collection/low_pressure_syndrome</a> <b>Secondary headache disorders</b> <a href="http://n.neurology.org/cgi/collection/secondary_headache_disorders">http://n.neurology.org/cgi/collection/secondary_headache_disorders</a>
<b>Permissions &amp; Licensing</b>	Information about reproducing this article in parts (figures, tables) or in its entirety can be found online at: <a href="http://www.neurology.org/about/about_the_journal#permissions">http://www.neurology.org/about/about_the_journal#permissions</a>
<b>Reprints</b>	Information about ordering reprints can be found online: <a href="http://n.neurology.org/subscribers/advertise">http://n.neurology.org/subscribers/advertise</a>

*Neurology*® is the official journal of the American Academy of Neurology. Published continuously since 1951, it is now a weekly with 48 issues per year. Copyright . All rights reserved. Print ISSN: 0028-3878. Online ISSN: 1526-632X.

