

Pearls & Oy-sters: Optic tract syndrome

Amadeo R. Rodriguez,
MD
Kesava Reddy, MB, BS,
FRCSC, FACS

Address correspondence and
reprint requests to Dr. Amadeo R.
Rodriguez, St. Joseph's
Healthcare CAHS Campus, 2757
King Street East, Hamilton,
Ontario, Canada L8G 5E4
arrodr@gmail.com

PEARLS

- The optic tract syndrome is characterized by a contralateral, incongruous homonymous hemianopia, contralateral relative afferent pupillary defect (RAPD), and optic atrophy due to retrograde axonal degeneration.
- Optic disc pallor often results in a pattern of bowtie atrophy of the eye with temporal field loss and atrophy of the upper and lower poles of the disc of the eye with nasal field loss.
- Visual acuity and color vision are usually normal unless there is bilateral involvement or extension to the chiasm or optic nerve.

OY-STERS

- Homonymous hemianopia is typically incongruous in optic tract lesions although this concept only applies if the defect is incomplete. Complete homonymous hemianopia is of no localizing value.
- Behr's pupil (larger pupil on the side opposite to the lesion) and pupillary hemiakinesia (Wernicke sign) are historical signs that are not helpful in the clinical setting.

The optic tract is a white matter band that projects from the chiasm to the lateral geniculate body. Given this particular anatomy, lesions of this structure may result in several typical clinical features which are often under-recognized. We present a case of massive recurrence of an epidermoid tumor of the cerebellopontine angle that presented with manifestations of optic tract involvement.

CASE REPORT A 46-year-old man presented with several months of right visual field deficit and memory loss. He had undergone incomplete resection of an epidermoid tumor of the left cerebellopontine angle 10 years prior to this presentation. On examination, visual acuity was normal and there was an obvious right homonymous hemianopia by confrontation with pallor of the optic discs. An MRI study of

the brain demonstrated a large lesion extending into the middle cranial fossa and involving the left optic tract (figure, A). He underwent surgery again and postoperative MRI showed a clear defect in the region of the left optic tract (figure, A). Pathology confirmed the recurrent nature of the epidermoid tumor.

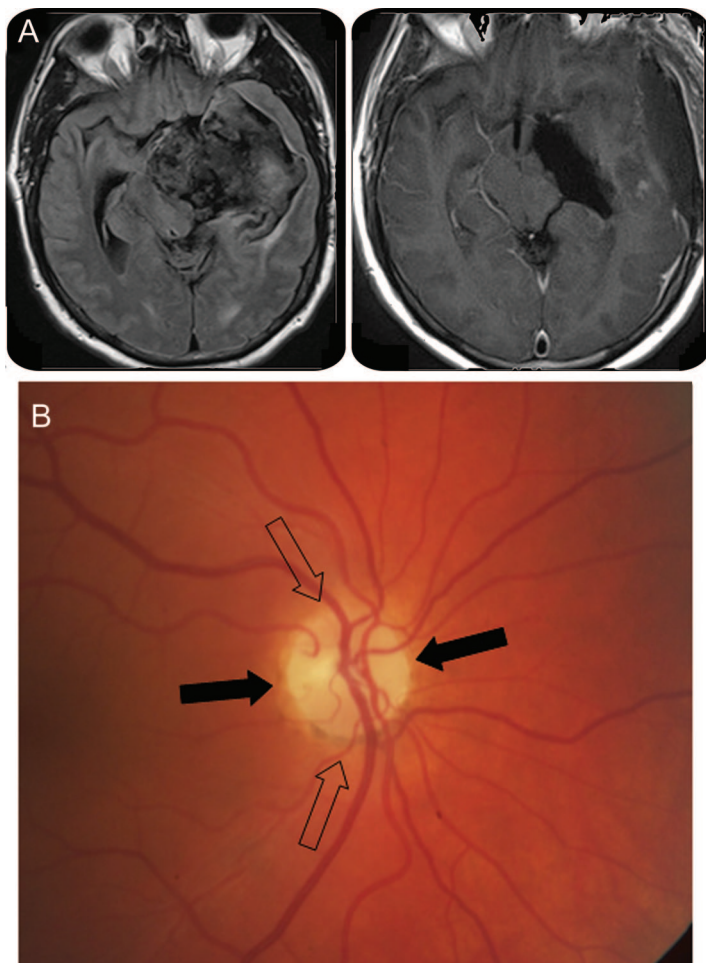
After surgery, he was referred to ophthalmology for evaluation of a complete left third nerve palsy as a result of intraoperative damage. His postoperative visual acuity was 20/25 in both eyes with normal color vision. There was a right RAPD. Funduscopy showed optic atrophy with a bowtie pattern of the right optic disc (figure, B), whereas the left disc showed mild, diffuse pallor. Goldmann visual field examination revealed a virtually complete right homonymous hemianopia. A year after a second operation, the left third nerve palsy improved and he only had a minor elevation deficit in the left eye but no diplopia in primary gaze or reading position.

DISCUSSION The optic tract contains ipsilateral retinal temporal fibers and contralateral retinal nasal fibers which have decussated in the optic chiasm. Most of the fibers project to the lateral geniculate body. These fibers are involved in processing the contralateral visual field and thus, damage causes contralateral homonymous field defect. If incomplete, the visual field defects are incongruous (i.e., asymmetric).¹ This is attributed to the fact that corresponding fibers from each eye are relatively separated anatomically in the optic tract.

The fibers contained in the optic tract are axons from the ganglion cells whose bodies are in the retina. Damage anywhere along these axons results in retrograde axonal degeneration that becomes clinically evident as pallor of the optic disc. This process typically occurs over 4 to 6 weeks.

Axons from the retina nasal to the optic disc and those corresponding to the nasal half of the macula (which are located temporal to the disc) are located mainly across the horizontal portion of the disc.

From the Divisions of Ophthalmology (A.R.R.) and Neuro-Surgery (K.R.), Department of Surgery, McMaster University, Hamilton, Canada.
Disclosure: Author disclosures are provided at the end of the article.



(A) Preoperative and postoperative MRI. (B) Bowtie atrophy. Fibers from the retina nasal to the optic disc and fibers nasal to the fovea but temporal to the disc project to the central portion of the optic nerve (black arrows). Fibers from the temporal retina form the poles of the optic disc (hollow arrows).

These axons subserve the entire temporal field in the contralateral eye and are destined to decussate in the chiasm. The poles of the optic disc are formed by fibers from the temporal retina (figure, B). As a consequence of this particular organization, damage to the decussating fibers results in atrophy across the central portion of the disc with sparing of the poles (bowtie atrophy), and damage to the temporal fibers mainly affects the poles with preservation of the central portion of the disc.² It is important to remember that bowtie atrophy can be unilateral (contralateral eye in optic tract lesions) or bilateral (chiasmal lesions).

Visual acuity and color vision are usually normal in an optic tract lesion because it only affects the

nasal macular fibers from the contralateral eye and the temporal macular fibers from the ipsilateral eye. In the event of bilateral involvement or extension to the chiasm or optic nerve,³ acuity and color vision become affected.

The optic tract also contains fibers involved in the pupillary light reflex. It is believed that pupillary fibers follow the same path as those involved in vision. However, pupillary fibers leave the optic tract before they reach the lateral geniculate body and project to the pretectal nuclei. Whereas in the event of incomplete optic tract damage and incongruous visual field loss, a RAPD is expected to be present in the eye with more extensive field loss, in complete lesions it is typically present in the eye with temporal field loss. This is due to the fact that the nasal retina is more extensive than the temporal retina and there are more crossed than uncrossed fibers with the proportion of decussating and nondecussating fibers estimated to be 53:47.⁴ As a result, each optic tract contains more pupillomotor input from the contralateral eye and lesions in this area cause a contralateral RAPD. There is evidence that the presence of a RAPD in the setting of an optic tract lesion reflects the difference in light sensitivity between the intact temporal and nasal hemifields rather than the absolute number of crossed vs uncrossed fibers.⁵ The recent discovery of melanopsin-expressing retinal ganglion cells that mediate the pupillary light reflex⁶ provides the intriguing yet unproven hypothesis that the retinal distribution of these may explain the origin of a RAPD in optic tract syndrome.

DISCLOSURE

Dr. Rodriguez received a speaker honorarium from Biogen Idec. Dr. Reddy reports no disclosures.

REFERENCES

1. Savino PJ, Paris M, Schatz NJ, Orr LS, Corbett JJ. Optic tract syndrome. *Arch Ophthalmol* 1978;96:656–663.
2. Unsold R, Hoyt WF. Band atrophy of the optic nerve. *Arch Ophthalmol* 1980;98:1637–1638.
3. Newman SA, Miller NR. Optic tract syndrome: neuro-ophthalmologic considerations. *Arch Ophthalmol* 1983;101:1241–1250.
4. Kupfer C, Chumbley L, Downer JC. Quantitative histology of optic nerve, optic tract and lateral geniculate nucleus of man. *J Anat* 1967;101:393–401.
5. Kardon R, Kawasaki A, Miller NR. Origin of relative afferent pupillary defect in optic tract lesions. *Ophthalmology* 2006;113:1345–1353.
6. Kawasaki A, Kardon RH. Intrinsically photosensitive retinal ganglion cells. *J Neuroophthalmol* 2007;27:195–204.

Neurology[®]

Pearls & Oy-sters: Optic tract syndrome

Amadeo R. Rodriguez and Kesava Reddy

Neurology 2010;75:e86-e87

DOI 10.1212/WNL.0b013e3181feb454

This information is current as of November 22, 2010

Updated Information & Services	including high resolution figures, can be found at: http://n.neurology.org/content/75/21/e86.full
References	This article cites 6 articles, 0 of which you can access for free at: http://n.neurology.org/content/75/21/e86.full#ref-list-1
Citations	This article has been cited by 1 HighWire-hosted articles: http://n.neurology.org/content/75/21/e86.full##otherarticles
Subspecialty Collections	This article, along with others on similar topics, appears in the following collection(s): Optic nerve http://n.neurology.org/cgi/collection/optic_nerve Pupils http://n.neurology.org/cgi/collection/pupils Visual fields http://n.neurology.org/cgi/collection/visual_fields
Permissions & Licensing	Information about reproducing this article in parts (figures, tables) or in its entirety can be found online at: http://www.neurology.org/about/about_the_journal#permissions
Reprints	Information about ordering reprints can be found online: http://n.neurology.org/subscribers/advertise

Neurology® is the official journal of the American Academy of Neurology. Published continuously since 1951, it is now a weekly with 48 issues per year. Copyright © 2010 by AAN Enterprises, Inc.. All rights reserved. Print ISSN: 0028-3878. Online ISSN: 1526-632X.

