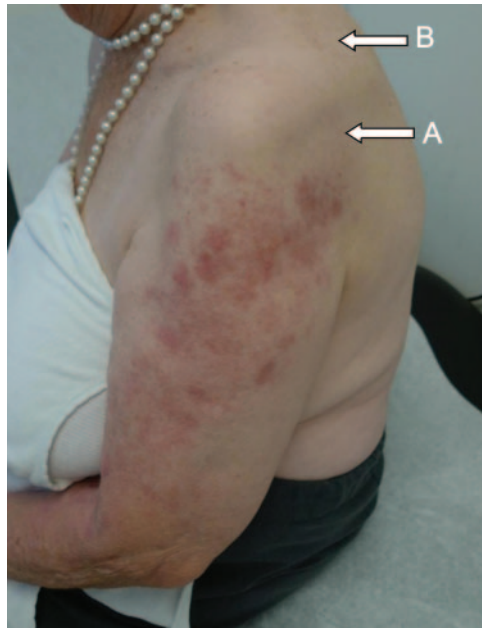


Teaching NeuroImages: MRI findings in varicella zoster brachial plexus neuritis

R.H. Chabot, MD
P.W. Wirtz, MD, PhD

Address correspondence and
reprint requests to Dr. R.H.
Chabot, Haga Teaching Hospital,
Department of Neurology,
Leyweg 275, 2545 CH The
Hague, the Netherlands
r.chabot@hagaziekenhuis.nl

Figure 1 C5 dermatomal rash and atrophy of the infraspinatus (A) and supraspinatus (B) muscles



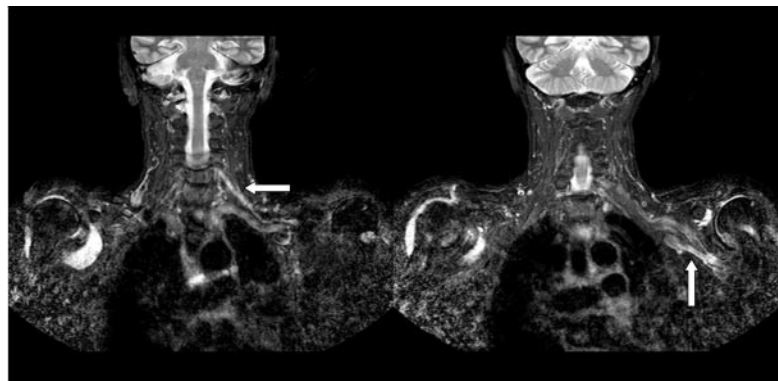
An 88-year-old woman with herpes zoster of the fifth cervical dermatome of the left arm (figure 1) developed left arm paresis. She had weakness of the deltoid, supraspinatus, and infraspinatus muscles (Medical Research Council [MRC] scale 2/5) and of the biceps, wrist extensors and flexors, and finger flexors (MRC scale 4/5). The biceps tendon reflex was absent, and the triceps tendon reflex was decreased.

Results for serum varicella zoster virus immunoglobulin M and immunoglobulin G were positive. EMG findings were consistent with left brachial plexopathy. MRI showed hyperintensity of the left brachial plexus (figure 2), consistent with herpes zoster plexopathy.¹

REFERENCE

1. Ismail A, Rao DG, Sharrack B. Pure motor herpes zoster induced brachial plexopathy. *J Neurol* 2009;256:1343–1345.

Figure 2 MRI of the chest showing the enhanced signal intensity of the left brachial plexus (arrows)



From the Department of Neurology, Haga Teaching Hospital, The Hague, the Netherlands.
Disclosure: The authors report no disclosures.

Neurology[®]

Teaching *NeuroImages*: MRI findings in varicella zoster brachial plexus neuritis

R.H. Chabot and P.W. Wirtz

Neurology 2011;76:e76

DOI 10.1212/WNL.0b013e31821527de

This information is current as of April 11, 2011

Updated Information & Services	including high resolution figures, can be found at: http://n.neurology.org/content/76/15/e76.full
References	This article cites 1 articles, 0 of which you can access for free at: http://n.neurology.org/content/76/15/e76.full#ref-list-1
Subspecialty Collections	This article, along with others on similar topics, appears in the following collection(s): All Clinical Neurology http://n.neurology.org/cgi/collection/all_clinical_neurology MRI http://n.neurology.org/cgi/collection/mri Neuropathic pain http://n.neurology.org/cgi/collection/neuropathic_pain Peripheral neuropathy http://n.neurology.org/cgi/collection/peripheral_neuropathy Viral infections http://n.neurology.org/cgi/collection/viral_infections
Permissions & Licensing	Information about reproducing this article in parts (figures, tables) or in its entirety can be found online at: http://www.neurology.org/about/about_the_journal#permissions
Reprints	Information about ordering reprints can be found online: http://n.neurology.org/subscribers/advertise

Neurology® is the official journal of the American Academy of Neurology. Published continuously since 1951, it is now a weekly with 48 issues per year. Copyright © 2011 by AAN Enterprises, Inc.. All rights reserved. Print ISSN: 0028-3878. Online ISSN: 1526-632X.

