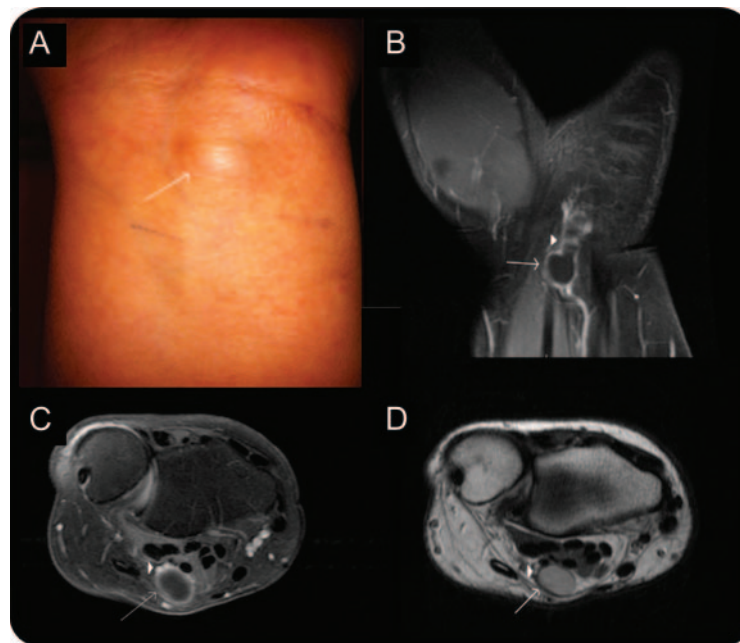


# Teaching NeuroImages: Ganglion cyst causing pure sensory ulnar neuropathy at the wrist

Chafic Karam, MD  
Colin C. Quinn, MD  
Sabrina Paganoni, MD,  
PhD  
William S. David, MD,  
PhD

Correspondence & reprint  
requests to Dr. Karam:  
chafickaram@gmail.com

**Figure** Picture and MRI of the left wrist show the ganglion cyst and ulnar nerve



(A) Ganglion cyst at the wrist. (B, C) (Coronal and axial views) STIR MRI of the wrist with contrast shows a ganglion cyst (arrow) compressing an enhancing ulnar nerve (arrowhead). (D) T1 MRI of the wrist (axial view) shows the cyst in relation to the anatomic structures.

A 32-year-old woman presented with left wrist pain and tender mass at the wrist for 1 month. She described left 4th and 5th digit tingling which worsened with palpation of the mass. Sensory nerve action potential of the digital sensory branch of the left ulnar nerve was of low amplitude and prolonged distal latency. Motor conduction studies and needle EMG were normal. Wrist MRI (figure) showed a ganglion cyst compressing the ulnar nerve which was surgically removed with partial improvement in the patient's symptoms. Ganglion cysts at the wrist are frequent and benign but can occasionally compro-

mise the median or ulnar nerve as shown in this case.<sup>1</sup>

## AUTHOR CONTRIBUTIONS

Chafic Karam: drafting/revising the manuscript, study concept or design, analysis or interpretation of data. Colin C. Quinn, MD: study concept or design, analysis or interpretation of data. Sabrina Paganoni, MD, PhD: study concept or design, analysis or interpretation of data. William S. David, MD, PhD: study concept or design, analysis or interpretation of data.

## REFERENCE

1. Erkin G, Uysal H, Keleş I, Aybay C, Ozel S. Acute ulnar neuropathy at the wrist: a case report and review of the literature. *Rheumatol Int* 2006;2:191–196.

From the Neuromuscular Diagnostics Center, Massachusetts General Hospital, Harvard Medical School, Boston, MA.

C. Karam serves on the editorial board of the *Neurology*® Resident & Fellow Section. C. Quinn, S. Paganoni, and W. David report no disclosures. Go to [Neurology.org](http://Neurology.org) for full disclosures.

# Neurology<sup>®</sup>

## Teaching *NeuroImages*: Ganglion cyst causing pure sensory ulnar neuropathy at the wrist

Chafic Karam, Colin C. Quinn, Sabrina Paganoni, et al.

*Neurology* 2012;79:e76

DOI 10.1212/WNL.0b013e318266200c

**This information is current as of August 20, 2012**

<b>Updated Information &amp; Services</b>	including high resolution figures, can be found at: <a href="http://n.neurology.org/content/79/8/e76.full">http://n.neurology.org/content/79/8/e76.full</a>
<b>References</b>	This article cites 1 articles, 0 of which you can access for free at: <a href="http://n.neurology.org/content/79/8/e76.full#ref-list-1">http://n.neurology.org/content/79/8/e76.full#ref-list-1</a>
<b>Subspecialty Collections</b>	This article, along with others on similar topics, appears in the following collection(s): <b>All Education</b> <a href="http://n.neurology.org/cgi/collection/all_education">http://n.neurology.org/cgi/collection/all_education</a> <b>All Neuromuscular Disease</b> <a href="http://n.neurology.org/cgi/collection/all_neuromuscular_disease">http://n.neurology.org/cgi/collection/all_neuromuscular_disease</a> <b>EMG</b> <a href="http://n.neurology.org/cgi/collection/emg">http://n.neurology.org/cgi/collection/emg</a> <b>MRI</b> <a href="http://n.neurology.org/cgi/collection/mri">http://n.neurology.org/cgi/collection/mri</a>
<b>Permissions &amp; Licensing</b>	Information about reproducing this article in parts (figures, tables) or in its entirety can be found online at: <a href="http://www.neurology.org/about/about_the_journal#permissions">http://www.neurology.org/about/about_the_journal#permissions</a>
<b>Reprints</b>	Information about ordering reprints can be found online: <a href="http://n.neurology.org/subscribers/advertise">http://n.neurology.org/subscribers/advertise</a>

*Neurology*® is the official journal of the American Academy of Neurology. Published continuously since 1951, it is now a weekly with 48 issues per year. Copyright © 2012 by AAN Enterprises, Inc.. All rights reserved. Print ISSN: 0028-3878. Online ISSN: 1526-632X.

