

Neurology[®]

Table of Contents

Volume 80, Number 20, May 14, 2013

Neurology.org

THE MOST WIDELY READ AND HIGHLY CITED PEER-REVIEWED
NEUROLOGY JOURNAL






IN FOCUS

- 1821 Spotlight on the May 14 issue
- 1849 This Week's *Neurology*[®] Podcast

EDITORIALS

- 1822 Changes in brain organization after TBI: Evidence from functional MRI findings
Y. Zhou and Y.W. Lui
- 1824 Human culture and the future dementia epidemic: Crisis or crossroads?
L.J. Whalley and K.A. Smyth

ARTICLES

- 1826 Traumatic brain injury impairs small-world topology
A.S. Pandit, P. Expert, R. Lambiotte, V. Bonnelle, R. Leech, F.E. Turkheimer, and D.J. Sharp
Editorial, p. 1822
- 1834 Newly diagnosed atrial fibrillation linked to wake-up stroke and TIA: Hypothetical implications
P.M. Riccio, F.R. Klein, F. Pagani Cassarà, F. Muñoz Giacomelli, M.E. González Toledo, J.M. Racosta, M. Delfitto, E.S. Roberts, M.C. Bahit, and L.A. Sposato

- 1841 White matter microstructure deteriorates across cognitive stages in Parkinson disease
T.R. Melzer, R. Watts, M.R. MacAskill, T.L. Pitcher, L. Livingston, R.J. Keenan, J.C. Dalrymple-Alford, and T.J. Anderson
- 1850 Serotonergic loss in motor circuitries correlates with severity of action-postural tremor in PD
C. Loane, K. Wu, P. Bain, D.J. Brooks, P. Piccini, and M. Politis
- 1856 The midbrain to pons ratio: A simple and specific MRI sign of progressive supranuclear palsy
L.A. Massey, H.R. Jäger, D.C. Paviour, S.S. O'Sullivan, H. Ling, D.R. Williams, C. Kallis, J. Holton, T. Revesz, D.J. Burn, T. Yousry, A.J. Lees, N.C. Fox, and C. Micallef

- 1862 Effect of 4-aminopyridine on vision in multiple sclerosis patients with optic neuropathy
L. Horton, A. Conger, D. Conger, G. Remington, T. Frohman, E. Frohman, and B. Greenberg
 

- 1867 Cerebellar learning distinguishes inflammatory neuropathy with and without tremor
P. Schwingenschuh, T.A. Saifee, P. Katschnig-Winter, M.M. Reilly, M.P. Lunn, H. Manji, M. Aguirregomozcorta, R. Schmidt, K.P. Bhatia, J.C. Rothwell, and M.J. Edwards
- 1874 Motor neuron involvement in multisystem proteinopathy: Implications for ALS
M. Benatar, J. Wu, C. Fernandez, C.C. Weihl, H. Katzen, J. Steele, B. Oskarsson, and J.P. Taylor
- 1881 Sensitivity and specificity of FTDC criteria for behavioral variant frontotemporal dementia
J.M. Harris, C. Gall, J.C. Thompson, A.M.T. Richardson, D. Neary, D. du Plessis, P. Pal, D.M.A. Mann, J.S. Snowden, and M. Jones
- 1888 Twenty-year changes in dementia occurrence suggest decreasing incidence in central Stockholm, Sweden
C. Qiu, E. von Strauss, L. Bäckman, B. Winblad, and L. Fratiglioni
Editorial, p. 1824
- 1895 Sodium valproate use is associated with reduced parietal lobe thickness and brain volume
H.R. Pardoe, A.T. Berg, and G.D. Jackson


VIEWS & REVIEWS

- 1901 Subcortical epilepsy?
R.A.B. Badawy, A. Lai, S.J. Vogrin, and M.J. Cook

CLINICAL/SCIENTIFIC NOTES

- 1908 Recurrent myoglobinuria and deranged acylcarnitines due to a mutation in the mtDNA MT-CO2 gene
C.R. Vissing, M. Duno, J.H. Olesen, J. Rafiq, L. Risom, E. Christensen, F. Wibrand, and J. Vissing

NEUROIMAGES

- 1911 Carotid dissection following a generalized tonic-clonic seizure
N.D. Child and G.D. Cascino

RESIDENT & FELLOW SECTION

- e207 Child Neurology: Zellweger syndrome
P.R. Lee and G.V. Raymond

CONTINUED

Neurology[®]

Table of Contents

continued



- e211 Clinical Reasoning: A 25-year-old man with headaches and collapse
S. Syed and A.J. Westwood
- e215 Teaching *NeuroImages*: T2 hyperintensities in neurofibromatosis type 1
A.P. Ostendorf, R.C. McKinstry, J.S. Shimony, and D.H. Gutmann

- e217 Teaching *NeuroImages*: Spontaneous tension pneumo-hydrocephalus may be related to otitis media and temporal bony defect
S.-H. Yu, C.-Z. Peng, K.-W. Cheng, and C.-K. How

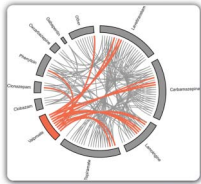
DEPARTMENT

A36 In the Next Issue of *Neurology*[®]

Podcast at www.neurology.org CME Video Patient Page LOE classification LOE recommendation



tinyurl.com/neurologyfan twitter.com/GreenJournal



Cover image: Antiepileptic drug combinations in intractable focal epilepsy cases 2009–2012, Comprehensive Epilepsy Program, Austin Health, Melbourne, Australia. See page 1895.

Publish Ahead of Print articles and editorials go live every Wednesday at 4 pm US Eastern time! Visit neurology.org.



Neurology[®] Online CME Program

Earn CME while reading *Neurology*. This program is available only to online *Neurology* subscribers. Simply read the articles marked CME, go to www.neurology.org, and click on CME. This will provide all of the information necessary to get started. The American Academy of Neurology (AAN) is accredited by the Accreditation Council for Continuing Medical Education (ACCME) to sponsor continuing medical education for physicians. *Neurology* is planned and produced in accordance with the ACCME Essentials. For more information, contact AAN Member Services at 800-879-1960.

Neurology®

80 (20)

Neurology 2013;80:e211-1911

This information is current as of January 1, 2013

Updated Information & Services

including high resolution figures, can be found at:
<http://n.neurology.org/content/80/20.full>

Permissions & Licensing

Information about reproducing this article in parts (figures, tables) or in its entirety can be found online at:
http://www.neurology.org/about/about_the_journal#permissions

Reprints

Information about ordering reprints can be found online:
<http://n.neurology.org/subscribers/advertise>

Neurology® is the official journal of the American Academy of Neurology. Published continuously since 1951, it is now a weekly with 48 issues per year. Copyright . All rights reserved. Print ISSN: 0028-3878. Online ISSN: 1526-632X.

