

# Clinical Reasoning:

## A 62-year-old man with right wrist drop

Giovanni Cirillo, MD  
Vincenzo Todisco, MD  
Alessandro Tessitore,  
MD, PhD  
Gioacchino Tedeschi,  
MD

Correspondence to  
Dr. Tedeschi:  
gioacchino.tedeschi@unina2.it

### SECTION 1

A 62-year-old man presented to our neurology outpatient clinic with a 3-week history of progressive right wrist drop. He had been complaining of generalized asthenia, numbness, and tingling involving the soles of both feet for the last year. He had a history of chronic renal failure due to type 2 diabetes, for which he was on maintenance hemodialysis. He had hypertension and hyperlipidemia, treated respectively with propranolol and simvastatin. He denied smoking and alcohol abuse.

Family history was unremarkable. General examination was normal, heart rate was 80 bpm, and orthostatism was not observed. Neurologic examination revealed mild ataxic gait with negative Romberg sign; right mild ptosis, which did not fluctuate after 60 sec-

onds of upward gaze; equally sized pupils, briskly reacting to light and accommodation; full range and no clinical evidence of extraocular movement fatigability. Medical Research Council strength score was 4/5 in distal muscles of upper and lower limbs, with the exception of 1/5 score in wrist and finger extensors (extensor carpi ulnaris and radialis, extensor digitorum, extensor indicis); there was no evidence of fatigability. Deep tendon reflexes (DTRs) were symmetrically reduced. Sensory examination showed increased thermo-nociceptive and vibration threshold at distal lower limbs bilaterally.

### Question for consideration:

1. What is the differential diagnosis suggested by the clinical history and neurologic examination?

[GO TO SECTION 2](#)

## SECTION 2

Our patient presented with progressive right wrist and finger drop. This clinical presentation includes the following differential diagnosis:

1. Focal compression or entrapment of the radial nerve
2. Restricted forms of brachial plexitis and mono-neuritis of radial nerve
3. Multifocal motor neuropathy (MMN) with conduction blocks
4. Hereditary neuropathy with liability to pressure palsies (HNPP)
5. Neuromuscular junction (NMJ) disorders
6. CNS subacute lesions

Wrist and finger drop could be due to radial nerve focal compression by a number of causes, including nerve tumors (e.g., schwannomas). The focal entrapment of the posterior interosseous nerve (PIN, the radial nerve motor branch) at Frohse ligament manifests as finger drop with variable weakness of wrist extension and radial deviation of the extended wrist (PIN syndrome).

Numbness of the lateral dorsum of the hand (including thumb and proximal phalanges of index, middle, and ring fingers), associated with wrist and finger drop, is the common presentation of the Saturday night palsy, due to focal compression of the radial nerve at the spiral groove.

Subacute wrist drop, beginning with deep pain and followed by weakness, could be due to a limited form of brachial plexitis (Parsonage-Turner syndrome) or peripheral nerve vasculitis (mononeuritis multiplex).

MMN begins with a painless, usually distal, motor mononeuropathy (weakness of the wrist or foot drop), associated with conduction blocks and circulating anti-ganglioside antibodies.

HNPP is a dominantly inherited disorder characterized by multiple recurrent focal painless neuropathies caused by deletion of *PMP22* gene and provoked by slight or brief compression. In our case, the negative family history and late disease onset argued against this diagnosis.

Distal hand weakness also may be an atypical presentation of NMJ disorders<sup>1</sup> or CNS mass lesion and ischemic stroke (pseudoperipheral palsy) of the frontal (precentral gyrus) or parietal lobe (angular gyrus).<sup>2</sup>

Symmetrical sensory-motor impairment at distal lower limbs and reduced DTRs in a patient with diabetes and chronic renal failure would suggest a diagnosis of metabolic polyneuropathy with length-dependent pattern, characterized by distal clinical presentation, often symmetrical, first affecting the lower then upper extremities.

The differential diagnosis of a chronic sensory-motor neuropathy includes the following:

1. Metabolic polyneuropathy (diabetic, uremic, alcoholic, malnutrition)
2. Paraproteinemias and paraneoplastic-associated neuropathy
3. Chronic idiopathic inflammatory/dysimmune neuropathy (CIDP)
4. Hereditary motor and sensory neuropathy (HMSN)
5. Vasculitic neuropathy

Laboratory and instrumental examinations are mandatory for paraproteinemias and paraneoplastic-associated neuropathy, characterized by slowly progressive distal limb paresthesias, deep sensory loss, and gait ataxia.

CIDP is characterized by symmetrical proximal and distal weakness over more than 2 months, associated with absent/diminished DTRs and sensitive impairment. Other forms of chronic acquired polyneuropathy<sup>3</sup> include 1) distal acquired demyelinating symmetric neuropathy and 2) focal/multifocal acquired demyelinating sensory and motor neuropathy (the Lewis-Sumner syndrome), associated with motor and sensory deficits, asymmetrical distal presentation, and conduction blocks.

HMSN is a complex group of autosomal dominant, recessive, or X-linked inherited disorders, divided into demyelinating, axonal, and intermediate forms according to nerve conduction velocities (NCV). Most forms present with early onset of symmetrical distal limb weakness, sensory loss, pes cavus, altered nerve conduction studies (NCS), and a strong family history, although a de novo presentation is frequently observed.

Vasculitis affects systemic organs as well as peripheral nervous system and CNS. The clinical presentation of vasculitic neuropathies is an acute/subacute onset of mono/multiple painful neuritis or, rarely, bilateral, symmetric, distal sensory-motor polyneuropathy.

It is noteworthy that our patient also had a mild right ptosis. Unilateral ptosis, occurring with third nerve palsy or Horner syndrome, is unlikely because of undetected pupil and extraocular movement alterations. However, it could also suggest a diagnosis of myasthenia gravis (MG), even if the ptosis is not fluctuating and extraocular movements are in full range. In contrast, ptosis is less frequently observed in Lambert-Eaton myasthenic syndrome, typically characterized by fluctuating proximal limb weakness.

### Question for consideration:

1. Which investigations would you consider to distinguish among the differential diagnoses?

**GO TO SECTION 3**

### SECTION 3

To narrow the diagnosis, blood tests, NCS, needle EMG, and brain MRI are necessary. Blood count, complete metabolic panel, HbA<sub>1c</sub>, serum protein electrophoresis/immunofixation electrophoresis, C-reactive

protein, GM-1 antibodies, antinuclear antibodies, and rheumatoid factor were all normal except for creatinine 3.3 mg/dL (normal 0.8–1.2), blood glucose 180 mg/dL (normal 90–110), and HbA<sub>1c</sub> 7.8% (normal <6). Creatine kinase levels and anti-neoplastic markers were within normal ranges. Brain MRI is consistent with chronic cerebrovascular disease. A lumbar puncture was performed and all studies were negative.

NCS in the lower limbs showed sensory nerve action potential amplitude at the lower limit of normal range in the superficial peroneal (left 3.3  $\mu$ V, right 3.5  $\mu$ V; normal >3) and sural (left 3.4  $\mu$ V, right 3.8  $\mu$ V; normal >3) nerves, and slightly reduced sensitive NCV (36–38 m/s) consistent with incipient damage of sensory peripheral nerve fibers. The distal motor response of the right deep peroneal nerve from extensor digitorum brevis with single stimulus was normal. The subsequent stimulus at fibular head showed a 50% drop of the amplitude and 40% drop of the area of the compound muscle action potential (CMAP). A second distal stimulus at the ankle showed a 58% drop of the amplitude and 60% drop of the area of the CMAP, compared to the first one (figure, A).

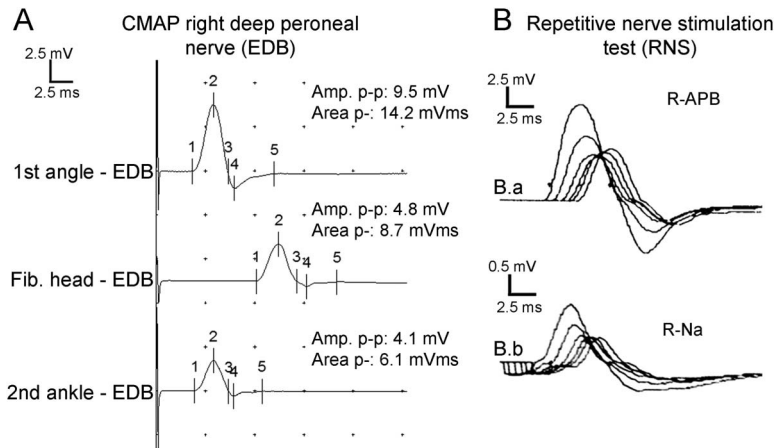
Needle EMG of the upper limbs (right biceps and finger extensors) and lower limbs (left quadriceps and anterior tibialis) was normal.

#### Question for consideration:

1. What is the most likely diagnosis?

**GO TO SECTION 4**

**Figure** Nerve conduction study findings of right deep peroneal nerve and repetitive nerve stimulation test findings



(A) Distal nerve stimulation at ankle from extensor digitorum brevis (EDB) resulted in a normal compound muscle action potential (CMAP); subsequent single proximal stimulus at fibular head showed a significant drop of CMAP amplitude and area, which was still evident at the second single distal stimulus. (B) Postexercise 3-Hz repetitive nerve stimulation (RNS) of the right median to abductor pollicis brevis (R-APB) (B.a) and right facial to nasalis (R-Na) (B.b) muscles showed significant decrement in both muscles. Amp. p-p = amplitude measured at peak to peak; Area p- = area of negative peak; Fib. head = fibular head.

## SECTION 4

The significant reduction of CMAP amplitude/area following fibular head stimulation would suggest a conduction block of right deep peroneal nerve. However, the reduction of the amplitude/area of the distal CMAP after a second nerve stimulus at ankle is not consistent with a conduction block and is suggestive of NMJ disorder.

Therefore, a repetitive nerve stimulation (RNS) test at 3 Hz of the median nerve (recording from right abductor pollicis brevis [R-APB]) and facial nerve (from nasalis [R-Na]) was performed (figure, B). The RNS test showed significant reduction of motor response at basal and 1 minute after exercise (R-APB:  $-66.3\%$ ; R-Na:  $-46.2\%$ ) that is consistent with a marked alteration of neuromuscular transmission (table). A high titer of serum binding antibodies against acetylcholine receptors (anti-AchR Ab) (2 nmol/L, normal  $<0.25$ ) was detected.

Therefore, the diagnosis of seropositive MG was confirmed.

Chest CT scan ruled out the presence of thymic abnormalities (i.e., thymic hyperplasia or thymoma), usually correlated to high titer of anti-AchR Ab.

The patient started taking oral prednisone (25 mg/day) and pyridostigmine (120 mg/day) with complete resolution of right ptosis and wrist/finger drop. Six months follow-up demonstrated a long-lasting response to pharmacologic treatment.

**DISCUSSION** MG is an autoimmune disorder determining a postsynaptic defect in neuromuscular transmission. The presence of binding anti-AchR Ab is responsible for weakness that frequently involves extraocular, bulbar, and proximal extremity muscles.<sup>4</sup>

Whereas classic clinical presentations of MG usually lead to a straightforward diagnosis, a distal and asymmetric muscle weakness has been reported in several MG cases.<sup>1</sup> This atypical and unusual pattern of weakness can lead to diagnostic confusion, especially, as in our case, if the underlying diagnosis of

MG is not yet defined. Moreover, in the case of moderate to severe or untreated disease, muscle weakness may become fixed without showing any fluctuation. Distal weakness is observed in fewer than 5% of patients with MG at disease onset, usually involving hand muscles, particularly finger extensors.<sup>5-9</sup>

In patients presenting with anamnestic and clinical findings of fluctuating/fatigable weakness (particularly involving extraocular and bulbar muscles), diagnosis may be confirmed by electrophysiologic testing with RNS or single-fiber EMG, and serologic demonstration of binding anti-AchR or muscle-specific tyrosine kinase antibodies.<sup>10</sup>

The present case reports an atypical and uncommon presentation of a well-known neurologic disorder, showing that distal MG should be taken into account in the differential diagnostic process of focal distal limb weakness.

## AUTHOR CONTRIBUTIONS

Dr. G. Cirillo: clinical data acquisition, analysis and interpretation, drafting the manuscript, and review of literature. Dr. V. Todisco: clinical data acquisition, revising the manuscript. Dr. A. Tessitore: drafting and revising the manuscript. Prof. G. Tedeschi: supervising and editing the manuscript.

## STUDY FUNDING

No targeted funding reported.

## DISCLOSURE

Dr. Cirillo and Dr. Todisco report no disclosures. Dr. Tessitore has received speaker honoraria from Novartis, Schwarz Pharma/UCB, Lundbeck, and Glaxo. Prof. Tedeschi has received speaker honoraria from Sanofi-Aventis, Merck Serono, Bayer Schering Pharma, Novartis, and Biogen-Dompè AG; and has received funding for travel from Bayer Schering Pharma, Biogen-Dompè AG, Merck Serono, Novartis, and Sanofi Aventis. Go to [Neurology.org](http://Neurology.org) for full disclosures.

## REFERENCES

1. Nations SP, Wolfe GI, Amato AA, Jackson CE, Bryan WW, Barohn RJ. Distal myasthenia gravis. *Neurology* 1999;52:632-634.
2. Takqahashi N, Kawamura M, Araki S. Isolated hand palsy due to cortical infarction: localization of the motor hand area. *Neurology* 2002;58:1412-1414.
3. Köller H, Kieseier BC, Jander S, Hartung HP. Chronic inflammatory demyelinating polyneuropathy. *N Engl J Med* 2005;352:1343-1356.
4. Drachman DB. Myasthenia gravis. *N Engl J Med* 1994;330:1797-1810.
5. Iwasaki Y, Igarashi O, Kawabe K, et al. MG with distal muscle involvement. *Acta Neurol Scand* 2004;110:270.
6. Karacostas D, Mavromatis I, Georgakoudas G, Artemis N, Milonas I. Isolated distal hand weakness as the only presenting symptom of myasthenia gravis. *Eur J Neurol* 2002;9:429-430.
7. Scola RH, Iwamoto FM, Mainardi MA, et al. Distal myasthenia gravis: case report. *Arq Neuropsiquiatr* 2003;61:119-120.
8. Werner P, Kiechl S, Löscher W, Poewe W, Willeit J. Distal myasthenia gravis frequency and clinical course in a large prospective series. *Acta Neurol Scand* 2003;108:209-211.
9. Nicolle MW. Wrist and finger drop in myasthenia gravis. *J Clin Neuromuscul Dis* 2006;8:65-69.
10. Grob D, Brunner N, Namba T, Pagala M. Lifetime course of myasthenia gravis. *Muscle Nerve* 2008;37:141-149.

Table Repetitive nerve stimulation test findings <sup>a</sup>							
Muscle	Amp. p-, mV	4-1, %	6-1, %	Area, mV	4-1, %	6-1, %	Frequency, Hz
<b>R-APB</b>							
Basal	9.5	-53.5	-45.2	33.5	-57.8	-51.3	3
Postexercise 1 minute	9.4	-66.3	-62.1	34.0	-69.0	-66.5	3
<b>R-Na</b>							
Basal	1.3	-33.6	-30.7	3.4	-47.3	-45.6	3
Postexercise 1 minute	1.4	-46.2	-47.2	3.6	-59.6	-60.1	3

Abbreviations: Amp. p- = amplitude measured at negative peak; APB = abductor pollicis brevis; Na = nasalis.

<sup>a</sup>Significant reduction of motor response in both examined muscles at basal and after 1 minute of exercise.

# Neurology®

## Clinical Reasoning: A 62-year-old man with right wrist drop

Giovanni Cirillo, Vincenzo Todisco, Alessandro Tessitore, et al.

*Neurology* 2013;81:e81-e84

DOI 10.1212/WNL.0b013e3182a43b90

**This information is current as of September 9, 2013**

<b>Updated Information &amp; Services</b>	including high resolution figures, can be found at: <a href="http://n.neurology.org/content/81/11/e81.full">http://n.neurology.org/content/81/11/e81.full</a>
<b>References</b>	This article cites 10 articles, 2 of which you can access for free at: <a href="http://n.neurology.org/content/81/11/e81.full#ref-list-1">http://n.neurology.org/content/81/11/e81.full#ref-list-1</a>
<b>Subspecialty Collections</b>	This article, along with others on similar topics, appears in the following collection(s): <b>All Clinical Neurology</b> <a href="http://n.neurology.org/cgi/collection/all_clinical_neurology">http://n.neurology.org/cgi/collection/all_clinical_neurology</a> <b>All clinical neurophysiology</b> <a href="http://n.neurology.org/cgi/collection/all_clinical_neurophysiology">http://n.neurology.org/cgi/collection/all_clinical_neurophysiology</a> <b>Myasthenia</b> <a href="http://n.neurology.org/cgi/collection/myasthenia">http://n.neurology.org/cgi/collection/myasthenia</a>
<b>Errata</b>	An erratum has been published regarding this article. Please see <a href="#">next page</a> or: <a href="/content/81/18/1645.full.pdf">/content/81/18/1645.full.pdf</a>
<b>Permissions &amp; Licensing</b>	Information about reproducing this article in parts (figures, tables) or in its entirety can be found online at: <a href="http://www.neurology.org/about/about_the_journal#permissions">http://www.neurology.org/about/about_the_journal#permissions</a>
<b>Reprints</b>	Information about ordering reprints can be found online: <a href="http://n.neurology.org/subscribers/advertise">http://n.neurology.org/subscribers/advertise</a>

*Neurology*® is the official journal of the American Academy of Neurology. Published continuously since 1951, it is now a weekly with 48 issues per year. Copyright © 2013 American Academy of Neurology. All rights reserved. Print ISSN: 0028-3878. Online ISSN: 1526-632X.



resolution is an important attribute. As Dr. Zhu noted, advances in US technology permit visualization of nerve structures that was not possible a decade ago. Finally, as our editorial and Dr. Zhu highlight, real-time dynamic scanning of nerves is a critical advantage over MRI. All these considerations further confirm the utility of US in the evaluation of peripheral nerve disease.

© 2013 American Academy of Neurology

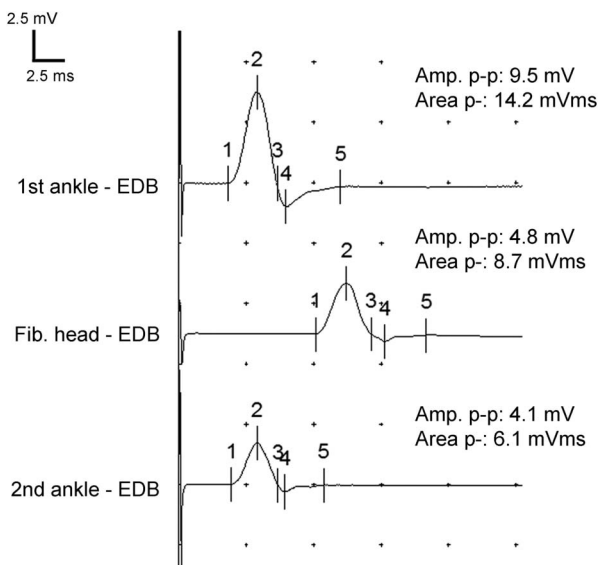
1. Padua L, Hobson-Webb LD. Ultrasound as the first choice for peripheral nerve imaging? *Neurology* 2013;80:1626–1627.
2. Wells PN, Liang HD, Young TP. Ultrasonic imaging technologies in perspective. *J Med Eng Technol* 2011;35:289–299.
3. Liu F, Zhu J, Wei M, Bao Y, Hu B. Preliminary evaluation of the sural nerve using 22-MHz ultrasound: a new approach for evaluation of diabetic cutaneous neuropathy. *PLoS One* 2012;7:e32730.
4. Zhu J, Liu F, Li D, Shao J, Hu B. Preliminary study of the types of traumatic peripheral nerve injuries by ultrasound. *Eur Radiol* 2011;21:1097–1101.

## CORRECTION

### Clinical Reasoning: A 62-year-old man with right wrist drop

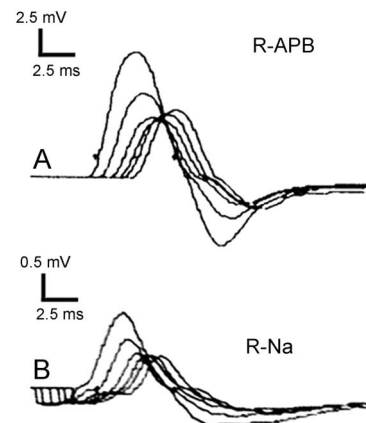
In the Resident & Fellow article “Clinical Reasoning: A 62-year-old man with right wrist drop” by G. Cirillo et al. (*Neurology*® 2013;81:e81–e84), there is an error in the corresponding author’s title, which should have read Prof. Tedeschi, as well as errors involving the figure. The published figure should have been split into 2 figures and the first y-axis label in figure 1, panel A, should have read “1st ankle – EDB.” See corrected figures with titles and legends below. The publisher regrets the errors.

**Figure 1** Nerve conduction study findings of right deep peroneal nerve



Distal nerve stimulation at ankle from extensor digitorum brevis (EDB) resulted in a normal compound muscle action potential (CMAP); subsequent single proximal stimulus at fibular head showed a significant drop of CMAP amplitude and area, which was still evident at the second single distal stimulus. Amp. p-p = amplitude measured at peak to peak; Area p- = area of negative peak; Fib. head = fibular head.

**Figure 2** Repetitive nerve stimulation test findings



3-Hz repetitive nerve stimulation of the right median to abductor pollicis brevis (R-APB) (A) and right facial to nasalis (R-Na) (B) muscles showed significant decrement in both muscles.

Author disclosures are available upon request ([journal@neurology.org](mailto:journal@neurology.org)).