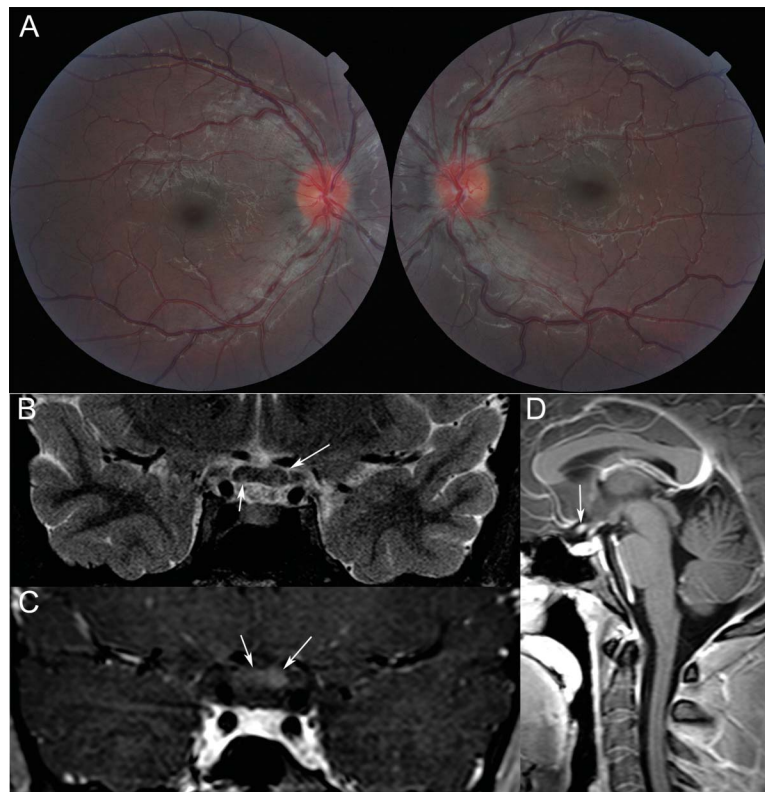


Teaching NeuroImages: Chiasmal enlargement and enhancement in Leber hereditary optic neuropathy

Elodie Ong, MD
Damien Biotti, MD
Lucie Abouaf, MD
Guy Louis-Tisserand,
MD
Caroline Tilikete, MD,
PhD
Alain Vighetto, MD

Correspondence to
Dr. Biotti:
damien.biotti@chu-lyon.fr

Figure Retinal photography and MRI of the chiasm



(A) Funduscopy reveals bilateral elevation and hyperemia (pseudooedema) of the optic discs. (B) T2 fluid-attenuated inversion recovery images show asymmetrical chiasmal hyperintensities and enlargement. (C, D) Axial and sagittal gadolinium-enhanced T1-weighted images show chiasmal enhancement (arrows).

A 19-year-old man was admitted for subacute severe painless bilateral loss of vision. The patient was known to be a healthy carrier of the mitochondrial G11778A mutation, with a family history of Leber hereditary optic neuropathy. Funduscopy revealed bilateral optic disc elevation and hyperemia (figure). Goldmann visual fields demonstrated large central scotomas in both eyes. CSF disclosed normal opening pressure and cytochemical examination. Unexpectedly, brain MRI revealed an asymmetrical chiasmal enlargement and enhancement (figure). Similar cases have rarely been reported.^{1,2} These findings would suggest disruption of the blood–brain barrier at the early

stage of the disease,² likely due to an inflammatory-like mechanism.

AUTHOR CONTRIBUTIONS

Elodie Ong: drafting/revising the manuscript, analysis or interpretation of data, accepts responsibility for conduct of research and final approval, acquisition of data. Damien Biotti: drafting/revising the manuscript, study concept or design, analysis or interpretation of data, accepts responsibility for conduct of research and final approval, acquisition of data, study supervision. Lucie Abouaf: drafting/revising the manuscript, accepts responsibility for conduct of research and final approval, acquisition of data. Guy Louis-Tisserand: analysis or interpretation of data, accepts responsibility for conduct of research and final approval, acquisition of data. Caroline Tilikete: drafting/revising the manuscript, study concept or design, accepts responsibility for conduct of research and final approval, study supervision. Alain Vighetto: drafting/revising the manuscript, analysis

From the Departments of Neurology (E.O., D.B., C.T., A.V.), Neuro-ophthalmology (D.B., L.A., C.T., A.V.), and Radiology (G.L.-T.), Hôpital Neurologique Pierre Wertheimer, Lyon; and Université de Lyon 1–Université Claude Bernard (D.B., L.A., C.T., A.V.), Lyon, France.

Go to Neurology.org for full disclosures. Funding information and disclosures deemed relevant by the authors, if any, are provided at the end of the article.

or interpretation of data, accepts responsibility for conduct of research and final approval, acquisition of data.

STUDY FUNDING

No targeted funding reported.

DISCLOSURE

The authors report no disclosures relevant to the manuscript. Go to Neurology.org for full disclosures.

REFERENCES

1. Vaphiades MS, Phillips PH, Turbin RE. Optic nerve and chiasmal enhancement in Leber hereditary optic neuropathy. *J Neuroophthalmol* 2003;23:104–105.
2. Lamirel C, Cassereau J, Cochereau I, et al. Papilloedema and MRI enhancement of the prechiasmal optic nerve at the acute stage of Leber hereditary optic neuropathy. *J Neurol Neurosurg Psychiatry* 2010;81:578–580.

Neurology®

Teaching *NeuroImages*: Chiasmal enlargement and enhancement in Leber hereditary optic neuropathy

Elodie Ong, Damien Biotti, Lucie Abouaf, et al.

Neurology 2013;81:e126-e127

DOI 10.1212/WNL.0b013e3182a95698

This information is current as of October 21, 2013

Updated Information & Services	including high resolution figures, can be found at: http://n.neurology.org/content/81/17/e126.full
References	This article cites 2 articles, 1 of which you can access for free at: http://n.neurology.org/content/81/17/e126.full#ref-list-1
Citations	This article has been cited by 1 HighWire-hosted articles: http://n.neurology.org/content/81/17/e126.full##otherarticles
Subspecialty Collections	This article, along with others on similar topics, appears in the following collection(s): All Neuro-ophthalmology http://n.neurology.org/cgi/collection/all_neuroophthalmology Mitochondrial disorders http://n.neurology.org/cgi/collection/mitochondrial_disorders MRI http://n.neurology.org/cgi/collection/mri Optic nerve http://n.neurology.org/cgi/collection/optic_nerve Visual loss http://n.neurology.org/cgi/collection/visual_loss
Permissions & Licensing	Information about reproducing this article in parts (figures, tables) or in its entirety can be found online at: http://www.neurology.org/about/about_the_journal#permissions
Reprints	Information about ordering reprints can be found online: http://n.neurology.org/subscribers/advertise

Neurology® is the official journal of the American Academy of Neurology. Published continuously since 1951, it is now a weekly with 48 issues per year. Copyright © 2013 American Academy of Neurology. All rights reserved. Print ISSN: 0028-3878. Online ISSN: 1526-632X.

