

Neurology[®]

Table of Contents

Volume 81, Number 19, November 5, 2013
Neurology.org

THE MOST WIDELY READ AND HIGHLY CITED PEER-REVIEWED
NEUROLOGY JOURNAL



IN FOCUS

- 1647 Spotlight on the November 5 Issue
- 1689 This Week's *Neurology*[®] Podcast

EDITORIALS

- 1648 Tumefactive multiple sclerosis and fingolimod: Immunotherapies and unintended consequences
F. Paul and D. Bourdette
- 1650 A physiologic biomarker for cerebral amyloid angiopathy
M.E. Gurol and S.M. Greenberg

IN MEMORIAM

- 1652 H. Royden Jones, Jr., MD (1936–2013)
M.J. Aminoff and J.A. Gutrecht

ARTICLES

- 1654 Tumefactive MS lesions under fingolimod: A case report and literature review
G. Pilz, A. Harrer, P. Wipfler, K. Oppermann, J. Sellner, F. Fazekas, E. Trinka, and J. Kraus
 **Editorial, p. 1648**
- 1659 Neurovascular decoupling is associated with severity of cerebral amyloid angiopathy
S. Peca, C.R. McCreary, E. Donaldson, G. Kumarpillai, N. Shobha, K. Sanchez, A. Charlton, C.D. Steinback, A.E. Beaudin, D. Flück, N. Pillay, G.H. Fick, M.J. Poulin, R. Frayne, B.G. Goodyear, and E.E. Smith
Editorial, p. 1650
- 1666 Cortical superficial siderosis and intracerebral hemorrhage risk in cerebral amyloid angiopathy
A. Charidimou, A.P. Peeters, R. Jäger, Z. Fox, Y. Vandermeeren, P. Laloux, J.-C. Baron, and D.J. Werring
- 1674 Poor reward sensitivity and apathy after stroke: Implication of basal ganglia
L. RoCHAT, M. Van der Linden, O. Renaud, J.-B. Epiney, P. Michel, R. Sztajzel, L. Spierer, and J.-M. Annoni

- 1681 MRI and pathology of REM sleep behavior disorder in dementia with Lewy bodies
M.E. Murray, T.J. Ferman, B.F. Boeve, S.A. Przybelski, T.G. Lesnick, A.M. Liesinger, M.L. Senjem, J.L. Gunter, G.M. Preboske, V.J. Lowe, P. Vemuri, B.N. Dugger, D.S. Knopman, G.E. Smith, J.E. Parisi, M.H. Silber, N.R. Graff-Radford, R.C. Petersen, C.R. Jack, Jr, D.W. Dickson, and K. Kantarci
- 1690 Primary leptomeningeal lymphoma: International Primary CNS Lymphoma Collaborative Group report
J.W. Taylor, E.P. Flanagan, B.P. O'Neill, T. Siegal, A. Omuro, L. DeAngelis, J. Baehring, R. Nishikawa, F. Pinto, M. Chamberlain, K. Hoang-Xuan, A. Gonzalez-Aguilar, T. Batchelor, J.-Y. Blay, A. Korfel, R.A. Betensky, M.-B.S. Lopes, and D. Schiff
 
- 1697 Extending the KCNQ2 encephalopathy spectrum: Clinical and neuroimaging findings in 17 patients
S. Weckhuysen, V. Ivanovic, R. Hendrickx, R. Van Coster, H. Hjalgrim, R.S. Møller, S. Grønberg, A.-S. Schoonjans, B. Ceulemans, S.B. Heavin, C. Eltze, R. Horvath, G. Casara, T. Pisano, L. Giordano, K. Rostasy, E. Haberlandt, B. Albrecht, A. Bevat, I. Benkel, S. Syrbe, B. Sheidley, R. Guerrini, A. Poduri, J.R. Lemke, S. Mandelstam, I. Scheffer, M. Angriman, P. Striano, C. Marini, A. Suls, and P. De Jonghe, on behalf of the KCNQ2 Study Group
- 1704 Presurgical connectome and postsurgical seizure control in temporal lobe epilepsy
L. Bonilha, J.A. Helpern, R. Sainju, T. Nesland, J.C. Edwards, S.S. Glazier, and A. Tabesh
- 1711 Pulse wave velocity is associated with β -amyloid deposition in the brains of very elderly adults
T.M. Hughes, L.H. Kuller, E.J.M. Barinas-Mitchell, R.H. Mackey, E.M. McDade, W.E. Klunk, H.J. Aizenstein, A.D. Cohen, B.E. Snitz, C.A. Mathis, S.T. DeKosky, and O.L. Lopez

CONTINUED

Neurology[®]

Table of Contents

continued



CLINICAL/SCIENTIFIC NOTES

- 1719 C9ORF72 transcription in a frontotemporal dementia case with two expanded alleles
J. Cooper-Knock, A. Higginbottom, N. Connor-Robson, N. Bayatti, J.J. Bury, J. Kirby, N. Ninkina, V.L. Buchman, and P.J. Shaw

NEUROIMAGES

- 1722 Isolated bipallidal lesions caused by extrapontine myelinolysis
G. Floris, F. Di Stefano, R. Melis, M.V. Cherchi, and F. Marrosu

RESIDENT & FELLOW SECTION

- e141 Clinical Reasoning: A woman with recurrent aphasia and visual field defects
B. Nourbakhsh, J.C. Rojas, C. Banerjee, R.L. Novakovic, and W. Warnack

- e145 Teaching *NeuroImages*: Hypomyelinating leukodystrophy with hypodontia due to *POLR3B*: Look into a leukodystrophy's mouth
M. Synofzik, G. Bernard, T. Lindig, and J. Gburek-Augustat
- e146 Teaching *NeuroImages*: Ma2 encephalitis presenting as acute panhypopituitarism in a young man
C.G. Bergner, C. Lang, A. Spreer, M. Bähr, A. Mohr, and M. Simons

WRITECLICK: EDITOR'S CHOICE

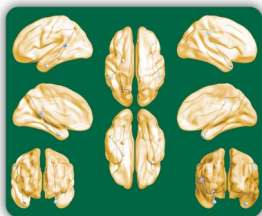
- 1724 Tadpole pupil
D.I. Friedman; Author Response: A. Kawasaki
- 1724 Practice patterns for intraoperative neurophysiologic monitoring
S.A. Skinner; Author Response: M.R. Nuwer, B.H. Cohen, K.M. Shepard

DEPARTMENT

- C3 In the Next Issue of *Neurology*[®]

Podcast at www.neurology.org CME Video Patient Page LOE classification LOE recommendation

Find us on Facebook tinyurl.com/neurologyfan twitter twitter.com/GreenJournal



Cover image: Presurgical connectivity differences in patients with temporal lobe epilepsy who did not achieve seizure freedom with surgery. Colorized by Graphics Editor, Cynthia Abair. See page 1704.

Look for **Publish Ahead of Print** articles and editorials under the Ahead of Print tab at Neurology.org

Neurology[®]

81 (19)

Neurology 2013;81:e141-1725

This information is current as of January 1, 2013

Updated Information & Services

including high resolution figures, can be found at:
<http://n.neurology.org/content/81/19.full>

Permissions & Licensing

Information about reproducing this article in parts (figures, tables) or in its entirety can be found online at:
http://www.neurology.org/about/about_the_journal#permissions

Reprints

Information about ordering reprints can be found online:
<http://n.neurology.org/subscribers/advertise>

Neurology® is the official journal of the American Academy of Neurology. Published continuously since 1951, it is now a weekly with 48 issues per year. Copyright . All rights reserved. Print ISSN: 0028-3878. Online ISSN: 1526-632X.

