

Neurology[®]

Table of Contents

Volume 81, Number 8, August 20, 2013
Neurology.org

THE MOST WIDELY READ AND HIGHLY CITED PEER-REVIEWED
NEUROLOGY JOURNAL



IN FOCUS


- 697 Spotlight on the August 20 Issue
773 This Week's *Neurology*[®] Podcast

EDITORIALS

- 698 Central adaptation after optic neuritis: Is the whole greater than the sum of its parts?
C.J. Lueck and F. Costello
- 700 Link between cardiovascular disease and spinal cord injury: New evidence and update
E.V. Kuklina and E.M. Hagen

ARTICLES

- 702 Temporal reorganization to overcome monocular demyelination
N. Raz, S. Chokron, T. Ben-Hur, and N. Levin
Editorial, p. 698
- 710 Responsiveness to reduced dosage of rituximab in Chinese patients with neuromyelitis optica
C.-S. Yang, L. Yang, T. Li, D.-Q. Zhang, W.-N. Jin, M.-S. Li, N. Su, N. Zhangning, Q. Liu, Z.-H. Shao, C. Yu, and F.-D. Shi
- 714 Anti-neurofascin antibody in patients with combined central and peripheral demyelination
N. Kawamura, R. Yamasaki, T. Yonekawa, T. Matsushita, S. Kusunoki, S. Nagayama, Y. Fukuda, H. Ogata, D. Matsuse, H. Murai, and J.-i. Kira
- 723 Cardiovascular disease and spinal cord injury: Results from a national population health survey
J.J. Cragg, V.K. Noonan, A. Krassioukov, and J. Borisoff
Editorial, p. 700
- 729 White matter hyperintensities on MRI in high-altitude U-2 pilots
S. McGuire, P. Sherman, L. Profenna, P. Grogan, J. Sladky, A. Brown, A. Robinson, L. Rowland, E. Hong, B. Patel, D. Tate, E.S. Kawano, P. Fox, and P. Kochunov

- 736 Impaired default network functional connectivity in autosomal dominant Alzheimer disease
J.P. Chhatwal, A.P. Schultz, K. Johnson, T.L.S. Benzinger, C. Jack, Jr, B.M. Ances, C.A. Sullivan, S.P. Salloway, J.M. Ringman, R.A. Koeppe, D.S. Marcus, P. Thompson, A.J. Saykin, S. Correia, P.R. Schofield, C.C. Rowe, N.C. Fox, A.M. Brickman, R. Mayeux, E. McDade, R. Bateman, A.M. Fagan, A.M. Goate, C. Xiong, V.D. Buckles, J.C. Morris, and R.A. Sperling
- 745 Early seizure onset and dysplastic lesion extent independently disrupt cognitive networks
B. Korman, P. Krsek, M. Duchowny, B. Maton, E. Pacheco-Jacome, and G. Rey
- 752 The semiology of tilt-induced psychogenic pseudosyncope
M.R. Tannemaat, J. van Niekerk, R.H. Reijntjes, R.D. Thijs, R. Sutton, and J.G. van Dijk




GLOBAL PERSPECTIVES

- 759 Current status of neurology in Croatia
I. Lušić


CLINICAL IMPLICATIONS OF NEUROSCIENCE RESEARCH

- 761 Monoamine transporters: Structure, regulation, and clinical implications
E.E. Benarroch

CLINICAL/SCIENTIFIC NOTES

- 769 Head drop in Huntington disease: Insights into the pathophysiology
F. Morgante, P. Girlanda, and D. Martino

- 770 Propofol-related infusion syndrome heralding a mitochondrial disease: Case report
M. Savard, N. Dupré, A.F. Turgeon, R. Desbiens, S. Langevin, and D. Brunet


VIDEO NEUROIMAGES

- 772 Nosography of the "essential": Volitional palatal tremor
J. Biller and A.J. Espay


CONTINUED


Neurology[®]

Table of Contents

continued



RESIDENT & FELLOW SECTION

- e47 Opinion and Special Articles: Electronic media in neurology education: Progress, promise, and pitfalls
S.E. Lakhan, D. Tepper, R.D. Snarski, and M.A. Mays

- e51 Teaching NeuroImages: Sciatic neuropathy after heroin abuse
H. Kumar and Y. Li
- e52 Teaching NeuroImages: Concurrent hemifacial spasm and trigeminal neuralgia due to vertebrobasilar dolichoectasia
S.E. Lakhan

WRITECLICK: EDITOR'S CHOICE

- 774 Nonmydriatic ocular fundus photography among headache patients in an emergency department
J. Appleton, D. Nicholl; Author Response: B.B. Bruce, V. Biousse, N.J. Newman
- 775 Clinicopathologic differences among patients with behavioral variant frontotemporal dementia
M. Hornberger; Author Response: M.F. Mendez

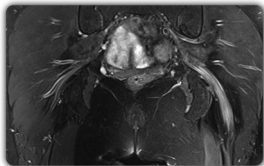
DEPARTMENT

- A39 In the Next Issue of *Neurology*[®]

 Podcast at www.neurology.org  CME  Video  Patient Page  LOE classification  LOE recommendation




tinyurl.com/neurologyfan  twitter.com/GreenJournal



Cover image: MRI of the hips shows a significantly enlarged left sciatic nerve with hyperintense signals and a normal appearing right sciatic nerve after heroin abuse. See page e51.

Look for **Publish Ahead of Print** articles and editorials under the Ahead of Print tab at Neurology.org



Neurology[®] Online CME Program

Earn CME while reading *Neurology*. This program is available only to online *Neurology* subscribers. Simply read the articles marked CME, go to www.neurology.org, and click on CME. This will provide all of the information necessary to get started. The American Academy of Neurology (AAN) is accredited by the Accreditation Council for Continuing Medical Education (ACCME) to sponsor continuing medical education for physicians. *Neurology* is planned and produced in accordance with the ACCME Essentials. For more information, contact AAN Member Services at 800-879-1960.

Neurology®

81 (8)

Neurology 2013;81:e51-775

This information is current as of January 1, 2013

Updated Information & Services

including high resolution figures, can be found at:
<http://n.neurology.org/content/81/8.full>

Permissions & Licensing

Information about reproducing this article in parts (figures, tables) or in its entirety can be found online at:
http://www.neurology.org/about/about_the_journal#permissions

Reprints

Information about ordering reprints can be found online:
<http://n.neurology.org/subscribers/advertise>

Neurology® is the official journal of the American Academy of Neurology. Published continuously since 1951, it is now a weekly with 48 issues per year. Copyright . All rights reserved. Print ISSN: 0028-3878. Online ISSN: 1526-632X.

