

Neurology[®]

Table of Contents

Volume 85, Number 22, December 1, 2015
Neurology.org

THE MOST WIDELY READ AND HIGHLY CITED PEER-REVIEWED
NEUROLOGY JOURNAL



IN FOCUS

- 1917 Spotlight on the December 1 Issue
- 1990 This Week's *Neurology*[®] Podcast

EDITORIALS


- 1918 Dipping to clear amyloid: Cerebrovascular reactivity and neurodegeneration—cause or effect?
S. Seshadri and M. Moonis
- 1920 Migraine makes the stroke grow faster?
G.E. Tietjen and S. Sacco

ARTICLES

- 1922 Amyloid burden and sleep blood pressure in amnesic mild cognitive impairment
T. Tarumi, T.S. Harris, C. Hill, Z. German, J. Riley, M. Turner, K.B. Womack, D.R. Kerwin, N.L. Monson, A.M. Stowe, D. Mathews, C.M. Cullum, and R. Zhang
Editorial, p. 1918
- 1930 Cerebral amyloid angiopathy and cognitive outcomes in community-based older persons
P.A. Boyle, L. Yu, S. Nag, S. Leurgans, R.S. Wilson, D.A. Bennett, and J.A. Schneider
- 1937 Raloxifene for women with Alzheimer disease: A randomized controlled pilot trial
V.W. Henderson, T. Ala, K.L. Sainani, A.L. Bernstein, B.S. Stephenson, A.C. Rosen, and M.R. Farlow
 
- 1945 Sensitivity to acute cerebral ischemic injury in migraineurs: A retrospective case-control study
J. Mawet, K. Eikermann-Haerter, K.-Y. Park, J. Helenius, A. Daneshmand, L. Pearlman, R. Avery, A. Negro, M. Velioglu, E.M. Arsava, H. Ay, and C. Ayata
 **Editorial, p. 1920**
- 1950 Moderate alcohol intake reduces risk of ischemic stroke in Korea
S.J. Lee, Y.-J. Cho, J.G. Kim, Y. Ko, K.-S. Hong, J.-M. Park, K. Kang, T.H. Park, S.-S. Park, K.B. Lee, J.K. Cha, D.-H. Kim, J. Lee, J.-T. Kim, J. Lee, J.S. Lee, M.S. Jang, M.-K. Han, P.B. Gorelick, and H.-J. Bae, on behalf of the CRCS-5 Investigators

- 1957 Quality of life in patients with TIA and minor ischemic stroke
R.S. Sangha, F.Z. Caprio, R. Askew, C. Corado, R. Bernstein, Y. Curran, I. Ruff, D. Cella, A.M. Naidech, and S. Prabhakaran
- 1964 Electrophysiologic features of SYT2 mutations causing a treatable neuromuscular syndrome
R.G. Whittaker, D.N. Herrmann, B. Bansagi, B.A.S. Hasan, R.M. Lofra, E.L. Logigian, J.E. Sowden, J.L. Almodovar, J.T. Littleton, S. Zuchner, R. Horvath, and H. Lochmüller
- 1972 Differences in the burden of psychiatric comorbidity in MS vs the general population
R.A. Marrie, J.D. Fisk, H. Tremlett, C. Wolfson, S. Warren, A. Tennakoon, S. Leung, and S.B. Patten, on behalf of the CIHR Team in the Epidemiology and Impact of Comorbidity on Multiple Sclerosis
OPEN

VIEWS & REVIEWS

- 1980 Endovascular vs medical management of acute ischemic stroke
C.-J. Chen, D. Ding, R.M. Starke, P. Mehndiratta, R.W. Crowley, K.C. Liu, A.M. Southerland, and B.B. Worrall


CLINICAL/SCIENTIFIC NOTES

- 1991 Dramatic worsening of adult-onset X-linked adrenoleukodystrophy after head trauma
F. Bouquet, C. Dehais, M. Sanson, C. Lubetzki, and C. Louapre

NEUROIMAGES

- 1994 Chronic CSF leak causing syringomyelia and pseudo-Arnold-Chiari malformation
R.M. Smith, I. Garza, and C.E. Robertson
- 1995 Lou Gehrig and the ALS split hand
M.C. Kiernan and M.R. Turner

RESIDENT & FELLOW SECTION

- e162 Pearls & Oy-sters: Cerebral venous sinus thrombosis involving a persistent falcine sinus
I. Lee, J. Leach, T. Tomsick, and M.L. Flaherty

CONTINUED

Neurology[®]

Table of Contents

continued



e165 Clinical Reasoning: A 48-year-old man with walking difficulty
D. Kalladka, A. Iqbal, E. MacDuff, and J. Overell

e170 Clinical Reasoning: Juvenile neurocognitive decline: A "snaky" diagnosis
N.M. Allen, A. Shahwan, C. Madigan, T. Nestor, and M.D. King



WRITECLICK[®] EDITOR'S CHOICE

1996 Owl's eye sign: A rare neuroimaging finding in flail arm syndrome
D.C. Khandelwal; Author Response: R. Shukla

1996 Epilepsy after aneurysmal subarachnoid hemorrhage: A population-based, long-term follow-up study
N.K. Sethi; Author Response: J.M. Huttunen, M.I. Kurki, M. von und zu Fraunberg, T. Koivisto, A. Ronkainen, J. Rinne, J.E. Jääskeläinen, R. Kalviainen, A. Immonen

UPDATE

1997 Migraine prevention with a supraorbital transcutaneous stimulator: A randomized controlled trial

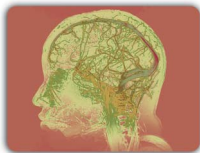
DEPARTMENT

In the Next Issue of *Neurology*[®]

Podcast at Neurology.org CME Video Patient Page LOE classification LOE recommendation



tinyurl.com/neurologyfan twitter.com/GreenJournal



Cover image: Contrast-enhanced MRV showing thrombosis of deep and persistent falx sinuses in a symptomatic patient. Colorized by Cindy Abair, *Neurology* Senior Graphics Editor. See page e162.

Look for **Publish Ahead of Print** articles and editorials under the Ahead of Print tab at Neurology.org



Neurology[®] Online CME Program

Earn CME while reading *Neurology*. This program is available only to online *Neurology* subscribers. Simply read the articles marked CME, go to Neurology.org, and click on CME. This will provide all of the information necessary to get started. The American Academy of Neurology (AAN) is accredited by the Accreditation Council for Continuing Medical Education (ACCME) to sponsor continuing medical education for physicians. *Neurology* is planned and produced in accordance with the ACCME Essentials. For more information, contact AAN Member Services at 800-879-1960.

Neurology[®]

85 (22)
Neurology 2015;85:e170-1997

This information is current as of January 1, 2015

Updated Information & Services

including high resolution figures, can be found at:
<http://n.neurology.org/content/85/22.full>

Permissions & Licensing

Information about reproducing this article in parts (figures, tables) or in its entirety can be found online at:
http://www.neurology.org/about/about_the_journal#permissions

Reprints

Information about ordering reprints can be found online:
<http://n.neurology.org/subscribers/advertise>

Neurology® is the official journal of the American Academy of Neurology. Published continuously since 1951, it is now a weekly with 48 issues per year. Copyright . All rights reserved. Print ISSN: 0028-3878. Online ISSN: 1526-632X.

