

SIGMAR1 mutation associated with autosomal recessive Silver-like syndrome

OPEN 

Alejandro Horga, MD*
Pedro J. Tomaselli, MD*
Michael A. Gonzalez,
PhD
Matilde Laurà, PhD
Francesco Muntoni, MD
Adnan Y. Manzur, MD
Michael G. Hanna, FRCP
Julian C. Blake, MRCP
Henry Houlden, PhD
Stephan Züchner, MD
Mary M. Reilly, FRCP

Correspondence to
Dr. Reilly:
m.reilly@ucl.ac.uk

ABSTRACT

Objective: To describe the genetic and clinical features of a simplex patient with distal hereditary motor neuropathy (dHMN) and lower limb spasticity (Silver-like syndrome) due to a mutation in the sigma nonopioid intracellular receptor-1 gene (*SIGMAR1*) and review the phenotypic spectrum of mutations in this gene.

Methods: We used whole-exome sequencing to investigate the proband. The variants of interest were investigated for segregation in the family using Sanger sequencing. Subsequently, a larger cohort of 16 unrelated dHMN patients was specifically screened for *SIGMAR1* mutations.

Results: In the proband, we identified a homozygous missense variant (c.194T>A, p.Leu65Gln) in exon 2 of *SIGMAR1* as the probable causative mutation. Pathogenicity is supported by evolutionary conservation, in silico analyses, and the strong phenotypic similarities with previously reported cases carrying coding sequence mutations in *SIGMAR1*. No other mutations were identified in 16 additional patients with dHMN.

Conclusions: We suggest that coding sequence mutations in *SIGMAR1* present clinically with a combination of dHMN and pyramidal tract signs, with or without spasticity, in the lower limbs. Preferential involvement of extensor muscles of the upper limbs may be a distinctive feature of the disease. These observations should be confirmed in future studies. *Neurology*® 2016;87:1607-1612

GLOSSARY

ALS = amyotrophic lateral sclerosis; **CMT** = Charcot-Marie-Tooth disease; **dHMN** = distal hereditary motor neuropathy; **dHMN-J** = distal hereditary motor neuropathy and pyramidal features identified in the Jerash region of Jordan; **ER** = endoplasmic reticulum; **ExAC** = Exome Aggregation Consortium database; **HSP** = hereditary spastic paraplegia; **MAF** = minor allele frequency; **MRC** = Medical Research Council; **σ1R** = sigma-1 receptor; **SIGMAR1** = sigma nonopioid intracellular receptor-1 gene; **UTR** = untranslated region; **WES** = whole-exome sequencing.

The distal hereditary motor neuropathies (dHMN) comprise a heterogeneous group of diseases that share the common feature of slowly progressive, symmetrical, and distal-predominant neurogenic weakness and amyotrophy.¹ There is phenotypic and genetic overlap between dHMN and other hereditary neuropathies and motor neuron disorders such as axonal forms of Charcot-Marie-Tooth disease (CMT2), juvenile amyotrophic lateral sclerosis (ALS), and hereditary spastic paraplegia (HSP). *BSCL2*- and *REEP1*-related disorders are an example of this overlap as autosomal dominant mutations in these genes can cause dHMN with upper limb predominance, pure HSP, or spastic paraplegia with amyotrophy of hands (Silver syndrome) or hands and feet (table 1).²⁻⁶

Homozygous mutations in the sigma nonopioid intracellular receptor-1 gene (*SIGMAR1*) have been reported as a cause of dHMN and juvenile ALS.^{7,8} Here we describe a patient with a Silver-like syndrome carrying a homozygous mutation in *SIGMAR1* and review the

Supplemental data
at Neurology.org

*These authors contributed equally to this work.

From the MRC Centre for Neuromuscular Diseases (A.H., P.J.T., M.L., M.G.H., J.C.B., H.H., M.M.R.), UCL Institute of Neurology, Queen Square, London, UK; Department of Human Genetics and Hussman Institute for Human Genomics (M.A.G., S.Z.), Miller School of Medicine, University of Miami; The Genesis Project Foundation (M.A.G.), Miami, FL; The Dubowitz Neuromuscular Centre (F.M., A.Y.M.), UCL Institute of Child Health, London; and Department of Clinical Neurophysiology (J.C.B.), Norfolk and Norwich University Hospital, Norwich, UK.

Go to Neurology.org for full disclosures. Funding information and disclosures deemed relevant by the authors, if any, are provided at the end of the article. The Article Processing Charge was paid by MRC.

This is an open access article distributed under the terms of the Creative Commons Attribution License 4.0 (CC BY), which permits unrestricted use, distribution, and reproduction in any medium, provided the original work is properly cited.

Table 1 Genes and loci identified in distal hereditary motor neuropathies (dHMN) with upper motor neuron signs or with Silver syndrome

Gene/locus	Inheritance	Alternative name	MIM number
dHMN with upper motor neuron signs			
<i>SETX</i>	AD	ALS4	602433
<i>BSCL2</i>	AD	dHMN5	600794
<i>GARS</i>	AD	dHMN5	600794
4q34.3-q35.2	AD	HMSN5	600361
9p21.1-p12	AR	dHMN Jerash type	605726
Silver syndrome			
<i>BSCL2</i>	AD	SPG17	270685
<i>REEP1</i>	AD	SPG31	610250
<i>SPAST</i>	AD	SPG4	182601
4p16-p15	AD	SPG38	612335

AD = autosomal dominant; ALS = amyotrophic lateral sclerosis; AR = autosomal recessive; dHMN5 = distal hereditary motor neuropathy with upper limb predominance; HMSN = hereditary motor and sensory neuropathy; MIM number = catalogue assignment for the disease in the Mendelian Inheritance in Man system (omim.org/); SPG = spastic paraplegia.

phenotypic spectrum of mutations in this gene. We suggest that coding sequence mutations present clinically with a combination of dHMN and pyramidal tract signs, with or without spasticity, in the lower limbs, adding *SIGMARI* to the list of genes that can cause overlapping motor neuron/nerve phenotypes.

METHODS The proband and 16 additional patients screened for *SIGMARI* mutations were identified from those attending neuropathy clinics at the National Hospital for Neurology and Neurosurgery, Queen Square, London, UK. The proband was investigated as part of a larger study to determine the genetic etiology in patients with inherited neuropathies using whole-exome sequencing (WES). All patients had undergone clinical and instrumental assessments during the routine diagnostic process and mutations in common neuropathy-related genes had been excluded in all cases. Nerve conduction studies, EMG, laboratory tests, and MRI scans were performed using standard methods. WES, Sanger sequencing, and in silico analysis methods are detailed in the supplementary material at Neurology.org.

Standard protocol approvals, registration, and patient consents. The study had ethical approval from the National Hospital for Neurology & Neurosurgery/Institute of Neurology Joint Research Ethics Committee. All patients gave written informed consent for genetic testing.

RESULTS Clinical features. The proband (figure, A) was the second child of healthy, nonconsanguineous parents of British and French descent. He walked independently at age 12 months. At age 3 years, he was noted to have bilateral foot drop and frequent falls and, over the following years, he developed progressive muscle weakness and atrophy in the lower limbs. Hand weakness and lower limb stiffness

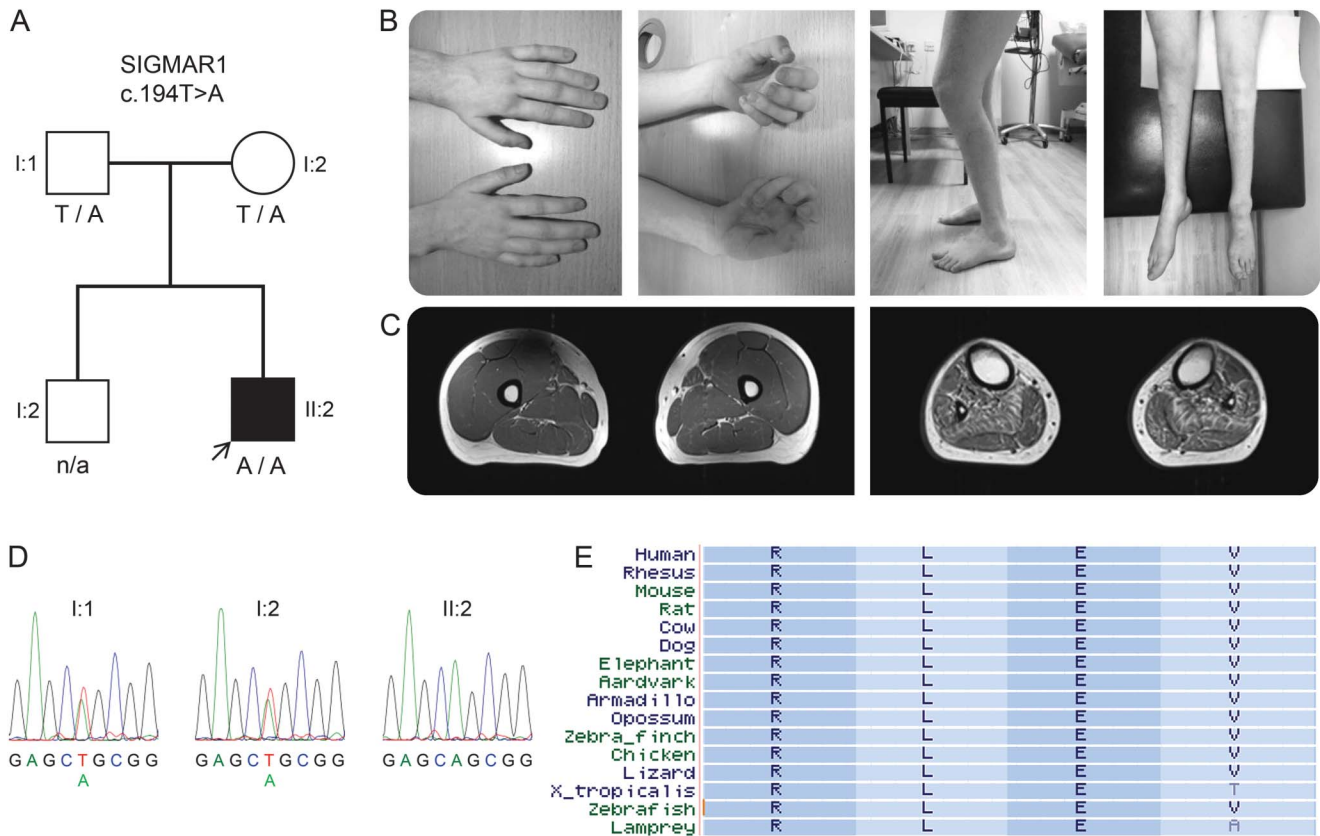
developed during the second decade of life. He underwent orthopedic surgery on his feet at ages 13–14 years and tendon-transfer surgery on both thumbs at ages 16–17 years with good functional outcomes. He has normal intellect, no sensory symptoms, and no sphincter problems. His family history was unremarkable and clinical and electrophysiologic examination of the parents was normal.

At age 17 years, on neurologic examination, he had clawed hands with no fixed contractures, bilateral finger and foot drop, knee bobbing, marked muscle atrophy from mid-forearms and knees down (figure, B), and weakness of wrist extension (Medical Research Council [MRC] grade 2/5 right, 4/5 left), finger extension (1/5), intrinsic hand muscles (0/5), ankle dorsiflexion (0/5 right, 1/5 left), ankle plantar flexion (1/5), toe extension (1/5), and toe flexion (0/5). Muscle strength in proximal muscles and finger flexors was normal. There was marked spasticity of the lower limbs and normal muscle tone in the upper limbs. Deep tendon reflexes were present in the upper limbs, increased at the knees, and absent at the ankles. Babinski sign was present bilaterally. Sensory and cranial nerve examinations were unremarkable. He walked with a combination of spastic and steppage gait. There was no scoliosis. Nerve conduction studies were consistent with a motor axonal neuropathy that was more severe in the lower limbs (table e-1). The superficial peroneal sensory action potential was normal and although the sural sensory nerve action potential amplitude was mildly reduced this may have been due to previous surgery rather than a sensory neuropathy. EMG of the biceps brachii showed features of chronic denervation. Brain and spinal cord MRIs were normal. Charcot-Marie-Tooth Neuropathy Score v.2 was 13.⁹

At age 20, neurologic examination confirmed progression of wrist extension weakness (MRC grade 1/5) causing hand drop and weakness of finger flexion (4/5) (video). The remainder of the examination was unchanged. MRI of the lower limbs demonstrated normal appearance of the thigh muscles and atrophy of all lower leg muscles with mild fatty replacement (figure, C). Serum creatine kinase level was normal at 184 IU/L.

Genetic studies. Molecular genetic analysis of the 17p11.2 chromosome region and direct sequencing of *MFN2*, *HSPB1*, *HSPB8*, *HSPB3*, *BSCL2*, and *GARS* genes revealed no pathogenic variants. WES on the proband revealed a total of 25,073 exonic variants (table e-2). The GEM.app software was used to focus on nonsynonymous, splice-site, and coding indel variants that were present in <5 families in the GEM.app database and that had a minor allele

Figure Family segregation, conservation of the *SIGMAR1* variant, and clinical images of the proband



(A) Segregation of the *SIGMAR1* variant c.194T>A in the family; genotypes are indicated below tested individuals. (B) Photographs of the proband show atrophy of intrinsic hand muscles, clawed hands, flexed knee posture (characteristic of knee bobbing), and atrophy of leg and foot muscles. (C) Axial T1-weighted MRI of the mid-thighs (left) and mid-legs (right) demonstrate normal appearance of the thigh muscles and atrophy of all lower leg muscles with mild fatty replacement especially of tibialis anterior, tibialis posterior, soleus, and peroneal muscles. (D) Sanger sequencing electropherograms demonstrate sequence variants in the proband and his parents. (E) Conservation of leucine (L) at amino acid position 65 of the σ -1 receptor encoded by *SIGMAR1*; a subset of 16 species were chosen, representing the 100 species available at the USCS browser.

frequency (MAF) <0.5% in the Exome Variant Server database (<http://evs.gs.washington.edu/EVS/>). From a total of 198 variants that met these filtering criteria, 9 of them involved genes associated with pure and complex inherited neuropathies/neuronopathies. Six were heterozygous variants in genes associated with autosomal recessive disorders (*ERCC6*, *LAMA2*, *MTPAP*, *MTTP*, *NTRK1*, and *PRX*). Two heterozygous variants were detected in genes associated with autosomal dominant spinal muscular atrophy and CMT2 (*BICD2* and *TRPV4*) and one homozygous variant was detected in *SIGMAR1*, a gene associated with autosomal recessive dHMN and juvenile ALS. The variants detected in *BICD2*, *TRPV4*, and *SIGMAR1* were validated by direct sequencing.

Cosegregation analyses allowed exclusion of the *BICD2* and *TRPV4* variants as pathogenic (e-Results) and confirmed that the proband's parents were heterozygous carriers of the *SIGMAR1* variant c.194T>A located in exon 2 (Ensembl ID ENST00000277010) (figure, D). This variant was

present in 4 out of 97,910 alleles (MAF 0.004%) in the Exome Aggregation Consortium database (ExAC <http://exac.broadinstitute.org/>), with none of the carriers being homozygous, and was absent in the GEM.app database and in an in-house exome database of 138 clinically and neuropathologically normal controls. c.194T>A leads to the substitution of nonpolar leucine for polar glutamine at amino acid position 65 (p.Leu65Gln), affects a highly conserved nucleotide and amino acid (figure, E), and is predicted as being deleterious or disease-causing by pathogenicity prediction tools (table e-3).

The 4 coding exons, intron/exon boundaries, and the 3'-untranslated region (3'-UTR) of *SIGMAR1* were Sanger sequenced in the proband and 16 additional unrelated dHMN patients. No other exonic or intronic changes were identified (table e-4).

DISCUSSION Using WES in a simplex patient with distal weakness and amyotrophy and lower limb spasticity and electrophysiologic features consistent with

a motor neuropathy, we have identified *SIGMAR1* as the probable causative gene. The phenotype of the patient mimics classical Silver syndrome except for the absence of upper limb predominance and the autosomal recessive pattern of inheritance; we termed this novel phenotype Silver-like syndrome. Pathogenicity of the *SIGMAR1* variant is supported by the in silico analysis described above and previous reports of individuals carrying homozygous mutations in the same gene, which are summarized in table 2.^{7,8}

Like the present case, affected individuals from previously reported families developed a combination of distal weakness in the upper ± lower limbs and pyramidal features in the lower limbs. Both our case and those with the mutation c.304G>C, located in exon 2, presented within the first 3 years of life and had severe involvement of forearm extensors and lower limb spasticity.⁷ Although the authors designated the cases with c.304G>C as juvenile ALS, they had no bulbar involvement and EMG evidence of

Table 2 Genetic and clinical features of patients with *SIGMAR1* mutations

	Present study, 2016	Li et al., 2015 ⁸	Al-Saif et al., 2011 ⁷
No. cases/kindred	1/1	3/1	6/1
Ethnicity	French-British	Chinese	Saudi Arabian
Type of mutation	Homozygous, missense	Homozygous, splice-site	Homozygous, missense
Exon/intron	Exon 2	Intron 1	Exon 2
cDNA change	c.194T>A	c.151+1G>T	c.304G>C
Protein change	p.Leu65Gln	p.Gly31_Ala50del ^a	p.Glu102Gln
Protein domain ¹⁴	Cytoplasmic	Cytoplasmic	Transmembrane
Disease onset, y	3	9-12	1-2
Motor delay	No	No	NA
Initial symptoms	Foot drop, frequent falls	Foot drop, pes varus	Lower limb spasticity and weakness
Hand involvement, y	12-13	11-15	9-10
Upper limb weakness	Yes; finger and wrist extensors > flexors	Yes; difficulty to straighten fingers at age 13 in one patient	Yes; paralysis of forearm extensors and triceps
Lower limb weakness	Yes	Yes	Yes
Distal predominant wasting/weakness	Yes	Yes	Upper limbs
Clinical fasciculations	No	No	NA
Upper limb spasticity	No	No	NA
Lower limb spasticity	Yes	No	Yes
Upper limb DTRs	Normal	NA	NA
Knee DTRs	Increased	Increased	Increased ^b
Ankle DTRs	Absent	Absent	Increased ^b
Babinski sign	Yes	Yes	NA
Sensory deficit	No	No	No
Bulbar involvement	No	No	No
Respiratory involvement	No	No	No
Cognitive impairment	No	No	No
Brain MRI	Normal	Normal	Normal
Spinal cord MRI	Normal	Normal	NA
Creatine kinase	Normal	Normal	NA
Phenotype description	dHMN with UMN signs/spasticity in lower limbs	dHMN with UMN signs in lower limbs	ALS; UMN signs/spasticity in lower limbs

Abbreviations: ALS = amyotrophic lateral sclerosis; dHMN = distal hereditary motor neuropathy; DTRs = deep tendon reflexes; *SIGMAR1* = sigma nonopioid intracellular receptor-1 gene; UMN = upper motor neuron.

Esembl reference sequences for *SIGMAR1*: ENSG00000147955; ENST00000277010.

^ac.151+1G>T causes an alternative splicing event that generates an in-frame deletion of 60 bp in exon 1 (c.92_151del, p. Gly31_Ala50del).

^bReported originally as lower limb spasticity and weakness accompanied by exaggerated tendon reflexes.

active denervation is not mentioned in the report. Thus, it appears that all these patients with exon 2 mutations share the same phenotype.

The cases with dHMN due to the splice-site mutation c.151+1G>T, resulting in deletion of the last 20 amino acids encoded by exon 1, had a later age at onset and lacked spasticity.⁸ As suggested by the authors, this phenotype is similar to that described in patients with dHMN and pyramidal features identified in the Jerash region of Jordan (dHMN-J) and mapped to 9p21.1-p12, which encompasses *SIGMAR1*.¹⁰ It is also significant that, as observed in our patient and those with the mutation c.304G>C, patients with dHMN-J had preferential involvement of forearm extensors over flexors.

The homozygous variant rs4879809 (9:34635598T>C, c.*31A>G), located in the 3'-UTR of *SIGMAR1*, has been detected in a consanguineous family with adult-onset ALS.¹¹ The authors suggested that c.*31A>G could contribute to the pathogenesis of ALS in this family. The allele C in 9:34635598, however, has a frequency of 99.5% in the ExAC database (99% homozygotes) and was present in all patients from our cohort and the proband's unaffected parents so we regarded it as nonpathogenic. Heterozygous 3'-UTR variants in *SIGMAR1* have been also identified in individuals with frontotemporal lobar degeneration–motor neuron disease but their pathogenic role is still unclear.^{12,13}

SIGMAR1 encodes for the sigma-1 receptor (σ_1R), an endoplasmic reticulum (ER) chaperone that resides at the specialized mitochondrial-associated ER membrane.¹⁴ σ_1R is involved in a wide array of cellular processes, including ER-mitochondrial Ca^{2+} signaling and cell survival, and is highly expressed in motor neurons of the brainstem and spinal cord.^{14,15} Recent studies suggest that loss of σ_1R function causes ER–mitochondria disconnection and ER stress activation and disrupts mitochondrial function and axonal transport, leading to motor neuron axonal degeneration followed by cell death.¹⁶ This dying-back degeneration process would be consistent with the distal predominant pattern of motor involvement seen in patients with *SIGMAR1* mutations.

Based on the present study and previous reports, we propose that coding sequence mutations in *SIGMAR1* manifest clinically with a combination of dHMN and pyramidal tract signs, with or without spasticity, in the lower limbs, and that preferential involvement of forearm extensors may be a distinctive feature of the disease. These observations should be confirmed in future studies.

AUTHOR CONTRIBUTIONS

A. Horga, P.J. Tomaselli: study design; acquisition, analysis, and interpretation of data; drafting and revising the manuscript. M.A. Gonzalez: acquisition, analysis, and interpretation of data; revising the manuscript.

M. Laurà, F. Muntoni, A.Y. Manzur, M.G. Hanna, J.C. Blake, H. Houlden: interpretation of data; revising the manuscript. S. Züchner: study concept and design; acquisition, analysis, and interpretation of data; revising the manuscript. M.M. Reilly: study supervision; study concept and design; acquisition, analysis, and interpretation of data; drafting and revising the manuscript.

STUDY FUNDING

Supported by an MRC Center grant (G0601943) and the National Institutes of Neurologic Diseases and Stroke and Office of Rare Diseases (U54NS065712). The INC (U54NS065712) is a part of the NCATS Rare Diseases Clinical Research Network (RDCRN). Also supported by the National Institute for Health Research University College London Hospitals Biomedical Research Centre and by the National Institute for Health Research Biomedical Research Centre at Great Ormond Street Hospital for Children NHS Foundation Trust and University College London.

DISCLOSURE

The authors report no disclosures relevant to the manuscript. Go to Neurology.org for full disclosures.

Received March 29, 2016. Accepted in final form June 24, 2016.

REFERENCES

1. Rossor AM, Kalmar B, Greensmith L, Reilly MM. The distal hereditary motor neuropathies. *J Neurol Neurosurg Psychiatry* 2012;83:6–14.
2. Silver JR. Familial spastic paraplegia with amyotrophy of the hands. *J Neurol Neurosurg Psychiatry* 1966;29:135–144.
3. Irobi J, Van den Bergh P, Merlini L, et al. The phenotype of motor neuropathies associated with BSLC2 mutations is broader than Silver syndrome and distal HMN type V. *Brain* 2004;127:2124–2130.
4. Auer-Grumbach M, Schlotter-Weigel B, Lochmuller H, et al. Phenotypes of the N88S Berardinelli-Seip congenital lipodystrophy 2 mutation. *Ann Neurol* 2005;57:415–424.
5. Goizet C, Depienne C, Benard G, et al. REEP1 mutations in SPG31: frequency, mutational spectrum, and potential association with mitochondrial morpho-functional dysfunction. *Hum Mutat* 2011;32:1118–1127.
6. Beetz C, Pieber TR, Hertel N, et al. Exome sequencing identifies a REEP1 mutation involved in distal hereditary motor neuropathy type V. *Am J Hum Genet* 2012;91:139–145.
7. Al-Saif A, Al-Mohanna F, Bohlega S. A mutation in sigma-1 receptor causes juvenile amyotrophic lateral sclerosis. *Ann Neurol* 2011;70:913–919.
8. Li X, Hu Z, Liu L, et al. A SIGMAR1 splice-site mutation causes distal hereditary motor neuropathy. *Neurology* 2015;84:2430–2437.
9. Murphy SM, Herrmann DN, McDermott MP, et al. Reliability of the CMT neuropathy score (second version) in Charcot-Marie-Tooth disease. *J Peripher Nerv Syst* 2011;16:191–198.
10. Christodoulou K, Zamba E, Tsingis M, et al. A novel form of distal hereditary motor neuronopathy maps to chromosome 9p21.1-p12. *Ann Neurol* 2000;48:877–884.
11. Ullah MI, Ahmad A, Raza SI, et al. In silico analysis of SIGMAR1 variant (rs4879809) segregating in a consanguineous Pakistani family showing amyotrophic lateral sclerosis without frontotemporal lobar dementia. *Neurogenetics* 2015;16:299–306.

12. Luty AA, Kwok JB, Dobson-Stone C, et al. Sigma non-opioid intracellular receptor 1 mutations cause frontotemporal lobar degeneration-motor neuron disease. *Ann Neurol* 2010;68:639–649.
13. Pickering-Brown S, Hardy J. Is SIGMAR1 a confirmed FTD/MND gene? *Brain* 2015;138:e393.
14. Hayashi T, Su TP. Sigma-1 receptor chaperones at the ER-mitochondrion interface regulate Ca(2+) signaling and cell survival. *Cell* 2007;131:596–610.
15. Mavlyutov TA, Epstein ML, Andersen KA, Ziskind-Conhaim L, Ruoho AE. The sigma-1 receptor is enriched in postsynaptic sites of C-terminals in mouse motoneurons: an anatomical and behavioral study. *Neuroscience* 2010;167:247–255.
16. Bernard-Marissal N, Medard JJ, Azzedine H, Chrast R. Dysfunction in endoplasmic reticulum-mitochondria crosstalk underlies SIGMAR1 loss of function mediated motor neuron degeneration. *Brain* 2015;138:875–890.

This Week's *Neurology*[®] Podcast



Reducing costs while enhancing quality of care in MS (see p. 1617)

This podcast begins and closes with Dr. Robert Gross, Editor-in-Chief, briefly discussing highlighted articles from the October 11, 2016, issue of *Neurology*. In the second segment, Dr. Mark Keegan talks with Dr. Ilya Kister about his paper on the various approaches neurologists may contribute to cost containment while maintaining and enhancing the quality of MS care. Dr. Andy Southerland interviews Dr. Lyell Jones about the topic of the Axon Registry and how it interfaces with practice and reimbursement for our “What’s Trending” feature of the week. This is part 2, with part 1 appearing last month. In the next part of the podcast, Dr. Bryan Eckerle focuses his interview with Dr. Steven Messé on a *Neurology Today* story about the AAN Guideline published in *Neurology* on the topic of recurrent stroke with patent foramen ovale.

Disclosures can be found at Neurology.org.

At Neurology.org, click on “RSS” in the Neurology Podcast box to listen to the most recent podcast and subscribe to the RSS feed.

CME Opportunity: Listen to this week’s *Neurology* Podcast and earn 0.5 AMA PRA Category 1 CME Credits[™] by answering the multiple-choice questions in the online Podcast quiz.

Upcoming Dates & Deadlines

Don't miss these important dates for the 2017 AAN Annual Meeting taking place April 22-28, 2017, in Boston, Massachusetts. Learn more at AAN.com/view/AM17.

- ▶ Abstract Submission Deadline: **October 24, 2016**
- ▶ Awards Application Deadline: **October 26, 2016**

Advancing Neurology. Advancing You



Neurology®

***SIGMAR1* mutation associated with autosomal recessive Silver-like syndrome**

Alejandro Horga, Pedro J. Tomaselli, Michael A. Gonzalez, et al.

Neurology 2016;87;1607-1612 Published Online before print September 14, 2016

DOI 10.1212/WNL.0000000000003212

This information is current as of September 14, 2016

Neurology® is the official journal of the American Academy of Neurology. Published continuously since 1951, it is now a weekly with 48 issues per year. Copyright © 2016 American Academy of Neurology. All rights reserved. Print ISSN: 0028-3878. Online ISSN: 1526-632X.



Updated Information & Services	including high resolution figures, can be found at: http://n.neurology.org/content/87/15/1607.full
Supplementary Material	Supplementary material can be found at: http://n.neurology.org/content/suppl/2016/09/14/WNL.0000000000003212.DC1 http://n.neurology.org/content/suppl/2016/09/14/WNL.0000000000003212.DC2
References	This article cites 16 articles, 3 of which you can access for free at: http://n.neurology.org/content/87/15/1607.full#ref-list-1
Citations	This article has been cited by 1 HighWire-hosted articles: http://n.neurology.org/content/87/15/1607.full##otherarticles
Subspecialty Collections	This article, along with others on similar topics, appears in the following collection(s): All Genetics http://n.neurology.org/cgi/collection/all_genetics All Neuromuscular Disease http://n.neurology.org/cgi/collection/all_neuromuscular_disease Amyotrophic lateral sclerosis http://n.neurology.org/cgi/collection/amyotrophic_lateral_sclerosis_peripheral_neuropathy Peripheral neuropathy http://n.neurology.org/cgi/collection/peripheral_neuropathy
Permissions & Licensing	Information about reproducing this article in parts (figures, tables) or in its entirety can be found online at: http://www.neurology.org/about/about_the_journal#permissions
Reprints	Information about ordering reprints can be found online: http://n.neurology.org/subscribers/advertise

Neurology® is the official journal of the American Academy of Neurology. Published continuously since 1951, it is now a weekly with 48 issues per year. Copyright © 2016 American Academy of Neurology. All rights reserved. Print ISSN: 0028-3878. Online ISSN: 1526-632X.

