

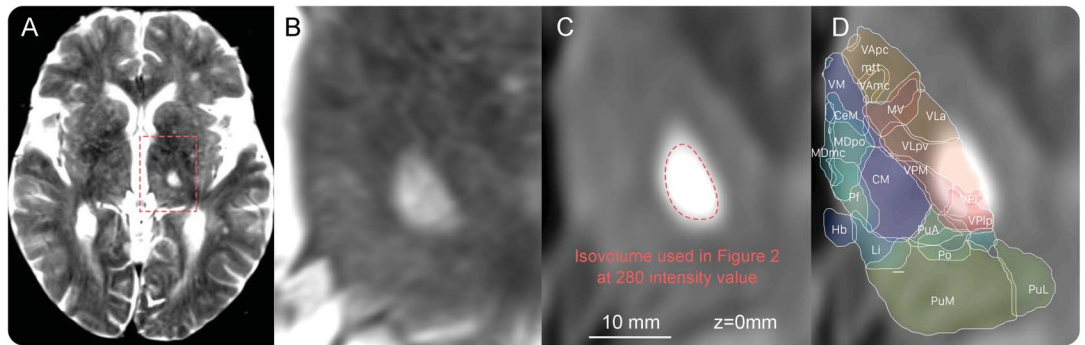
Teaching NeuroImages: Stroke mimicking thalamotomy

Cessation of tremor following ventrolateral thalamic ischemia

Andreas Horn, MD
Laura Kipp
Antonio Meola, MD
Andrea A. Kühn, MD
Christoph Leithner, MD

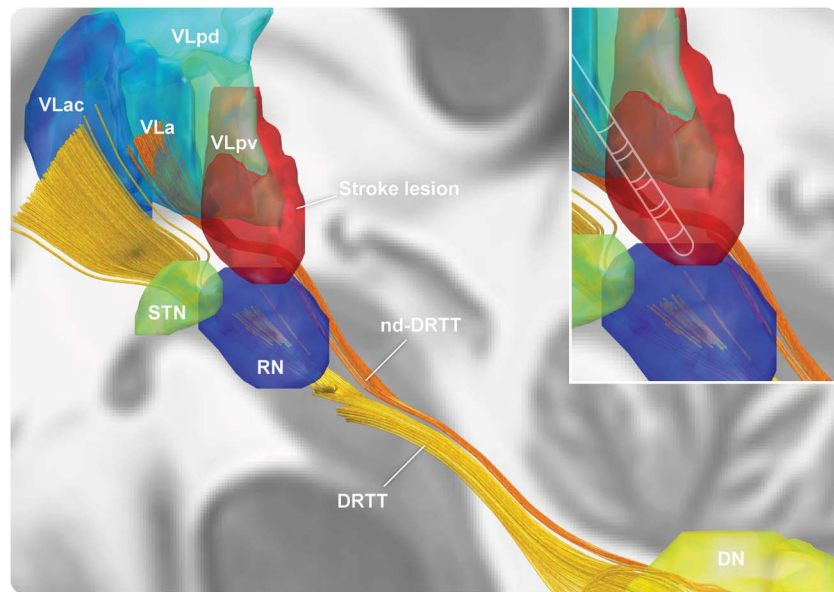
Correspondence to
Dr. Horn:
andreas.horn@charite.de

Figure 1 MRI slice views show stroke lesion site and spatial overlap with thalamic nuclei



(A, B) T2-weighted MRI. (C) Diffusion-weighted MRI of the left thalamus with isovolume at intensity value of 280 used to delineate the stroke lesion (figure 2). (D) Atlas structures locate the lesion to ventral lateral/ventral posterior nuclei (Jones nomenclature), which correspond to the ventralis intermedius in Walker nomenclature. For abbreviations, see reference 1.

Figure 2 3D visualization of the stroke lesion, subcortical nuclei, and dentatothalamic tracts



Visualization of stroke lesion, nuclei defined by the Morel atlas,¹ and 2 pathways of the dentatorubrothalamic tract.² The nondecussating dentatorubrothalamic (nd-DRTT) tract passes through the lesion. The enlarged picture shows the typical location of a DBS electrode with target nucleus ventralis intermedius electrode as placed in patients predominantly suffering from tremor, falling inside the stroke lesion. DN = dentate nucleus. For other abbreviations, see reference 1.

Download teaching slides:
Neurology.org

From the Department of Neurology (A.H., L.K., A.A.K., C.L.), Charité–University Medicine (CVK), Berlin, Germany; Movement Disorders Unit (A.H., A.A.K.), Charité–University Medicine (CVK), Berlin, Germany; Berenson-Allen Center for Noninvasive Brain Stimulation (A.H.), Department of Neurology, Beth Israel Deaconess Medical Center, Harvard Medical School, Boston, MA; Department of Neurosurgery (A.M.), Brigham and Women’s Hospital, Boston, MA; NeuroCure–Cluster of Excellence (A.A.K.); Berlin School of Mind and Brain (A.A.K.); and Deutsches Zentrum für Neurodegenerative Erkrankungen (A.A.K.), Berlin, Germany.

Go to Neurology.org for full disclosures. Funding information and disclosures deemed relevant by the authors, if any, are provided at the end of the article.

A 76-year-old woman with right-sided tremor-dominant idiopathic Parkinson disease was admitted due to sudden-onset right leg palsy, right hemihypesthesia, and slurred speech but cessation of resting tremor. MRI showed recent infarction in the left thalamus (figure 1). Spatial analysis performed with Lead-DBS software (www.lead-dbs.org) located the lesion to left ventrolateral and ventroposterior nuclei¹ (Jones nomenclature), corresponding to the ventrointermediate nucleus (Walker nomenclature), the typical deep brain stimulation target for tremor. The analysis showed that the (nondecussating) dentatothalamic tract,² which plays a prominent role in tremor pathophysiology, passes through the lesion (figure 2).

AUTHOR CONTRIBUTIONS

Dr. Horn wrote the manuscript and performed spatial analyses. L. Kipp provided and worked up the clinical case as physician of care together with Dr. Leithner. Dr. Meola provided the atlas of the dentatorubrothalamic tract and revised the manuscript. Prof. Kühn revised the manuscript and provided advice regarding spatial analyses. Dr. Leithner supervised and planned the manuscript, revised the manuscript, and worked up the clinical case as principal physician of care.

STUDY FUNDING

No targeted funding reported.

DISCLOSURE

A. Horn is supported by a grant from the German Research Association (DFG grant KFO247), Stiftung Charité, Berlin Institute of Health, and Prof. Klaus Thiemann Foundation. L. Kipp reports no disclosures relevant to the manuscript. A. Meola is supported by an NIH award (R25CA089017) and reports no conflicts of interest. A. Kühn received honoraria from St Jude Medical and Medtronic, travel grants from Ipsen Pharma and Boston Scientific, consultancies from Boston Scientific, and is supported by a grant from the German Research Association (DFG grant KFO247). C. Leithner reports no disclosures relevant to the manuscript. Go to Neurology.org for full disclosures.

REFERENCES

1. Krauth A, Blanc R, Poveda A, Jeanmonod D, Morel A, Székely G. A mean three-dimensional atlas of the human thalamus: generation from multiple histological data. *Neuroimage* 2010;49:2053–2062.
2. Meola A, Comert A, Yeh FC, Sivakanthan S, Fernandez-Miranda JC. The nondecussating pathway of the dentatorubrothalamic tract in humans: human connectome-based tractographic study and microdissection validation. *J Neurosurg* 2015;124:1406–1412.

Neurology®

Teaching *NeuroImages*: Stroke mimicking thalamotomy: Cessation of tremor following ventrolateral thalamic ischemia

Andreas Horn, Laura Kipp, Antonio Meola, et al.

Neurology 2016;87:e208-e209

DOI 10.1212/WNL.0000000000003263

This information is current as of October 24, 2016

Updated Information & Services	including high resolution figures, can be found at: http://n.neurology.org/content/87/17/e208.full
Supplementary Material	Supplementary material can be found at: http://n.neurology.org/content/suppl/2016/10/24/WNL.0000000000003263.DC1
References	This article cites 2 articles, 0 of which you can access for free at: http://n.neurology.org/content/87/17/e208.full#ref-list-1
Subspecialty Collections	This article, along with others on similar topics, appears in the following collection(s): All Cerebrovascular disease/Stroke http://n.neurology.org/cgi/collection/all_cerebrovascular_disease_stroke All Movement Disorders http://n.neurology.org/cgi/collection/all_movement_disorders Infarction http://n.neurology.org/cgi/collection/infarction Surgery/Stimulation http://n.neurology.org/cgi/collection/surgery-stimulation Tremor http://n.neurology.org/cgi/collection/tremor
Permissions & Licensing	Information about reproducing this article in parts (figures, tables) or in its entirety can be found online at: http://www.neurology.org/about/about_the_journal#permissions
Reprints	Information about ordering reprints can be found online: http://n.neurology.org/subscribers/advertise

Neurology® is the official journal of the American Academy of Neurology. Published continuously since 1951, it is now a weekly with 48 issues per year. Copyright © 2016 American Academy of Neurology. All rights reserved. Print ISSN: 0028-3878. Online ISSN: 1526-632X.

