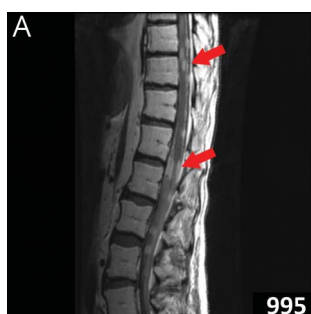
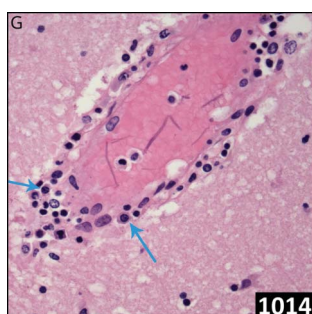
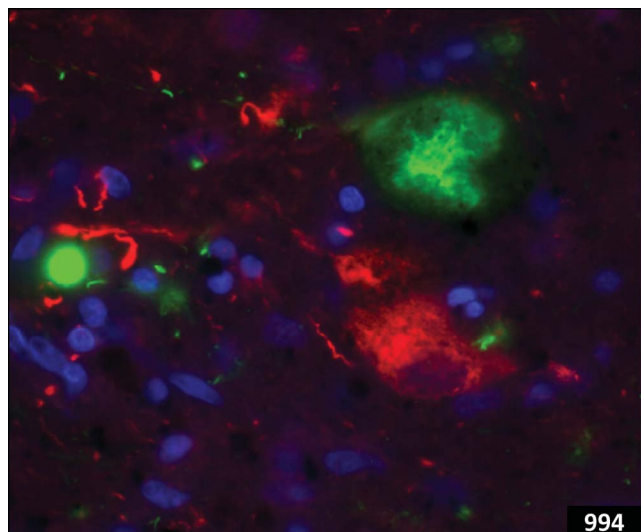Select figures listed on the Table of Contents only appear within the full-length articles online.

In Focus

- 977 **Spotlight on the May 21 issue**
- 978 **This Week's *Neurology*® Podcast**

Editorials

- 979 **Lamotrigine and hemophagocytic lymphohistiocytosis**
K.J. Meador and B.E. Gidal
- 981 **Oral anticoagulation in patients with “hemorrhagic-prone” vasculopathies: Overestimated risk?**
L.F. Maia and D. Wilson
- 983 **Advanced MRI in acute stroke: Is the whole penumbra salvageable?**
R. McKinley and R. Marshall

- 985 **Nusinersen for spinal muscular atrophy: Not just for babies?**

E. Ciafaloni and B.S. Russman

Articles: Short Format

Full articles at Neurology.org/N

- 987 **Hemophagocytic lymphohistiocytosis associated with the use of lamotrigine**

T. Kim, C.G. Kulick, C.M. Kortepeter, A. Brinker, and P. Waldron

[CME Course](#) [Editorial, p. 979](#)

- 988 **Long-term outcome in neuroZika: When biological diagnosis matters**

A. Lannuzel, J.-L. Fergé, Q. Lobjois, A. Signate, B. Rozé, B. Tressières, Y. Madec, P. Poullain, C. Herrmann, F. Najjioullah, E. McGovern, A.-C. Savidan, R. Valentino, S. Breurec, R. Césaire, E. Hirsch, P.-M. Lledo, G. Thiery, A. Cabié, F. Lazarini, and E. Roze

[Podcast](#)

- 989 **Oral anticoagulation in patients with chronic kidney disease: A systematic review and meta-analysis**

K. Malhotra, M.F. Ishfaq, N. Goyal, A.H. Katsanos, J. Parissis, A.W. Alexandrov, A.V. Alexandrov, and G. Tsivgoulis

[CME Course](#)

- 990 **MRI predicts intracranial hemorrhage in patients who receive long-term oral anticoagulation**

J. Martí-Fàbregas, S. Medrano-Martorell, E. Merino, L. Prats-Sánchez, R. Marín, R. Delgado-Mederos, A. Martínez-Domeño, P. Camps-Renom, E. Jiménez-Xarrié, M. Zedde, M. Gómez-Choco, L. Lara, A. Boix, A. Calleja, A.M. De Arce-Borda, Y. Bravo, B. Fuentes, M. Hernández-Pérez, D. Cánovas, L. Llull, B. Zandio, M. Freijo, I. Casado-Naranjo, J. Sanahuja, D. Cocho, J. Krupinski, A. Rodríguez-Campello, E. Palomeras, A. De Felipe, M. Serrano, E. Zapata-Arriaza, J. Zaragoza-Brunet, I. Díaz-Maroto, J. Fernández-Domínguez, A. Lago, J. Maestre, M. Rodríguez-Yáñez, and I. Gich, for the HERO Study Investigators

[Editorial, p. 981](#)

- 991 **Stroke incidence in young adults according to age, subtype, sex, and time trends**

M.S. Ekker, J.I. Verhoeven, I. Vaartjes, K.M. van Nieuwenhuizen, C.J.M. Klijn, and F.-E. de Leeuw

- 992 **Prognostic value of “tissue-based” definitions of TIA and minor stroke: Population-based study**

R. Hurford, L. Li, N. Lovett, M. Kubiak, W. Kuker, and P.M. Rothwell, for the Oxford Vascular Study

[Open Access Article](#)

- 993 **Collateral blood flow measurement with intravoxel incoherent motion perfusion imaging in hyperacute brain stroke**

C. Federau, M. Wintermark, S. Christensen, M. Mlynash, D.G. Marcellus, G. Zhu, B.W. Martin, M.G. Lansberg, G.W. Albers, and J.J. Heit

[Editorial, p. 983](#)

[Ahead of Print Articles and Editorials](#)

NPub.org/aheadofprint

Continued

994 **Coexisting Lewy body disease and clinical parkinsonism in frontotemporal lobar degeneration**

S.L. Forrest, D.R. Crockford, A. Sizemova, H. McCann, C.E. Shepherd, A.B. McGeachie, A.J. Affleck, F. Carew-Jones, L. Bartley, J.B. Kwok, W.S. Kim, E. Jary, R.H. Tan, C.V. McGinley, O. Piguet, J.R. Hodges, J.J. Kril, and G.M. Halliday

995 **Leptomeningeal metastases in glioma: The Memorial Sloan Kettering Cancer Center experience**

B.M. Andersen, C. Miranda, V. Hatzoglou, L.M. DeAngelis, and A.M. Miller

996 **Nusinersen in later-onset spinal muscular atrophy: Long-term results from the phase 1/2 studies**

B.T. Darras, C.A. Chiriboga, S.T. Iannaccone, K.J. Swoboda, J. Montes, L. Mignon, S. Xia, C.F. Bennett, K.M. Bishop, J.M. Shefner, A.M. Green, P. Sun, I. Bhan, S. Gheuens, E. Schneider, W. Farwell, and D.C. De Vivo, on behalf of the ISIS-396443-CS2/ISIS-396443-CS12 Study Groups

➔ Editorial, p. 985 [Open Access Article](#) ➔ [Class of Evidence](#)

What's Happening

997 **What's happening in *Neurology*[®]**

998 **What's happening in *Neurology*[®] Genetics**

Clinical Implications of Neuroscience Research

999 **Neurologic aspects of sweating and its disorders**

K. Minota, E.A. Coon, and E.E. Benarroch

Contemporary Issues

1006 **Financial relationships between neurologists and industry: The 2015 Open Payments database**

A. Ahlawat and P. Narayanaswami

Clinical/Scientific Notes

1014 **A rapidly fatal case of anti-NMDA receptor encephalitis due to acute brain edema and herniation**

S. Mammele, K.S. Thompson, and K.K. Abe

1017 **Blood pressure and dementia: What the SPRINT-MIND trial adds and what we still need to know**

R. Peters, J. Warwick, K.J. Anstey, and C.S. Anderson

Resident & Fellow Section

1019 **Global & Community Health: The Gorgas experience**

J.Z. Ding

e2507 **Pearls & Oy-sters: May-Thurner syndrome as a cause of embolic stroke of undetermined source in a young patient**

A. De León-Benedetti, E.T. Marulanda-Londoño, and A.M. Malik

e2510 **Teaching NeuroImages: Medically intractable epilepsy and ictal asystole treated with cardiac pacing**

N.M. Gregg, K.W. Hocquard, D.B. Burkholder, and T.D. Lagerlund

e2512 **Teaching NeuroImages: Advanced imaging of neurosarcoidosis with ⁶⁸Ga-DOTATATE PET/CT**

M. Unterrainer, V. Ruf, H. Ilhan, F. Vettermann, A. Holzgreve, C.C. Cyran, J.-C. Tonn, P. Bartenstein, and N.L. Albert

Global Perspectives

1022 **Acute stroke management: The plight of Nepal**

A. Chandra, P. Rajbhandari, and B. Pant

Disputes & Debates: Editors' Choice

1024 **Editors' note: Association between aspirin dose and subarachnoid hemorrhage from saccular aneurysms: A case-control study**

J.E. Siegler III and S. Galetta

1024 **Reader response: Association between aspirin dose and subarachnoid hemorrhage from saccular aneurysms: A case-control study**

S. Juvela

1025 **Reader response: Association between aspirin dose and subarachnoid hemorrhage from saccular aneurysms: A case-control study**

G. Vilanilam, M. Badi, L.P. Vemireddy, and N. Gopal

1025 **Author response: Association between aspirin dose and subarachnoid hemorrhage from saccular aneurysms: A case-control study**

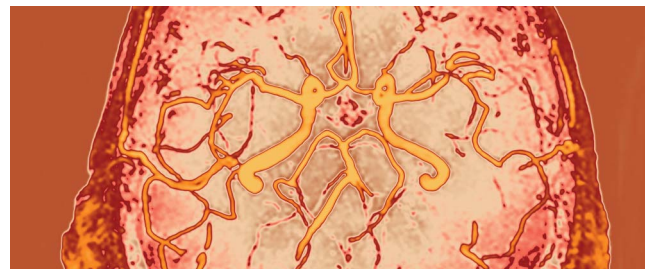
R. Du

Correction

1026 **Financial relationships between neurologists and Industry: The 2015 Open Payments database**

Department

In the Next Issue of *Neurology*[®]



➔ Cover image

Example of an IVIM penumbra perfusion lesion in a 67-year-old male patient with an acute M1 occlusion of the left middle cerebral artery. Stylized by Kaitlyn Aman Ramm, *Neurology* Editorial Assistant.

[See page 993](#)

Neurology[®]

92 (21)

Neurology 2019;92:e2510-1026

This information is current as of January 1, 2019

Updated Information & Services

including high resolution figures, can be found at:
<http://n.neurology.org/content/92/21.full>

Permissions & Licensing

Information about reproducing this article in parts (figures, tables) or in its entirety can be found online at:
http://www.neurology.org/about/about_the_journal#permissions

Reprints

Information about ordering reprints can be found online:
<http://n.neurology.org/subscribers/advertise>

Neurology® is the official journal of the American Academy of Neurology. Published continuously since 1951, it is now a weekly with 48 issues per year. Copyright . All rights reserved. Print ISSN: 0028-3878. Online ISSN: 1526-632X.

