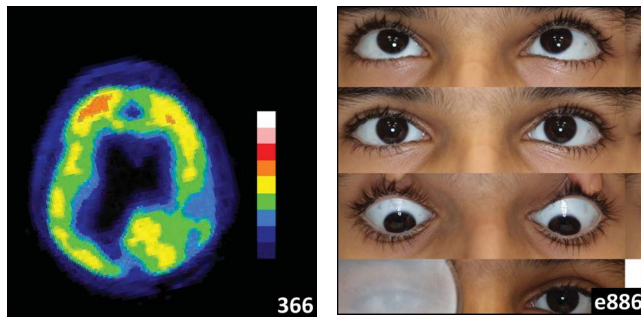
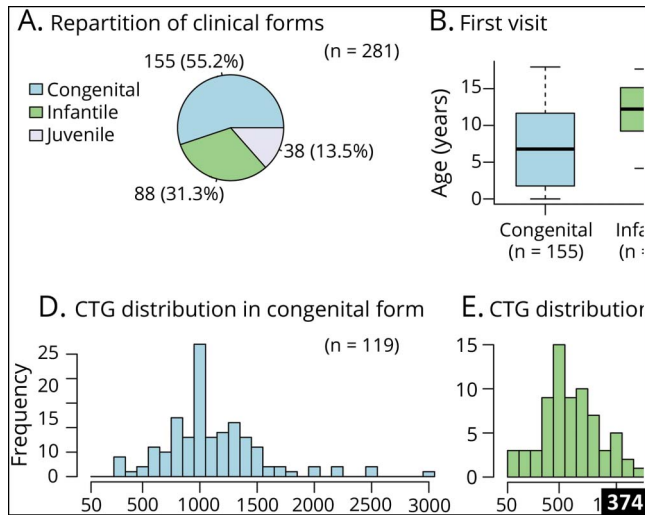
Select figures listed on the Table of Contents only appear within the full-length articles online.

In Focus

- 353 **Spotlight on the February 19 issue**
- 354 **This Week's *Neurology*® Podcast**

Editorials

- 355 **The emerging genetic landscape of cerebral white matter hyperintensities**
M. Fornage and A.H. Beecham
- 357 **Deciphering the causes of nontraumatic intracerebral hemorrhage**
T. Tatlisumak, R.H. Llinas, J. Martí-Fàbregas, and D.J. Seiffge
- 360 **Implications of cortical superficial siderosis in CAA: Superficial relationships**
S.M. Greenberg and E.E. Smith

- 362 **Physical exercise and activity may be important in reducing dementia risk at any age**
J.A. Mortimer and Y. Stern

Articles: Short Format

Full articles at Neurology.org/N

- 364 **Genetic variation in *PLEKHG1* is associated with white matter hyperintensities (n = 11,226)**
M. Traylor, D.J. Tozer, I.D. Croall, D.M. Liseicka Ford, A.O. Olorunda, G. Boncoraglio, M. Dichgans, R. Lemmens, J. Rosand, N.S. Rost, P.M. Rothwell, C.L.M. Sudlow, V. Thijs, L. Rutten-Jacobs, and H.S. Markus, on behalf of the International Stroke Genetics Consortium

[Open Access Article](#) [Editorial](#), p. 355

- 365 **Association of peripheral blood pressure with gray matter volume in 19- to 40-year-old adults**
H.L. Schaare, S. Kharabian Masouleh, F. Beyer, D. Kumral, M. Uhlig, J.D. Reinelt, A.M.F. Reiter, L. Lampe, A. Babayan, M. Erbey, J. Roebbig, M.L. Schroeter, H. Okon-Singer, K. Müller, N. Mendes, D.S. Margulies, A.V. Witte, M. Gaebler, and A. Villringer

- 366 **Microangiopathy underlying mixed-location intracerebral hemorrhages/microbleeds: A PiB-PET study**

H.-H. Tsai, M. Pasi, L.-K. Tsai, Y.-F. Chen, B.-C. Lee, S.-C. Tang, P. Fotiadis, C.-Y. Huang, R.-F. Yen, J.-S. Jeng, and M.E. Guroil

[Editorial](#), p. 357

- 367 **Hematoma location and morphology of anticoagulation-associated intracerebral hemorrhage**

D.J. Seiffge, S. Curtze, N. Dequatre-Ponchelle, A. Pezzini, T. Tatlisumak, C. Cordonnier, and D. Werring

- 368 **Prognostic relevance of cortical superficial siderosis in cerebral amyloid angiopathy**

F.A. Wollenweber, C. Opher, M. Zedde, C. Catak, R. Malik, M. Duering, M.J. Konieczny, R. Pascarella, R. Samões, M. Correia, J. Martí-Fàbregas, J. Linn, and M. Dichgans

[Editorial](#), p. 360

- 369 **Succinate links atrial dysfunction and cardioembolic stroke**

S.E. Nelson, Z. Ament, Z. Wolcott, R.E. Gerszten, and W.T. Kimberly

- 370 **Physical activity, common brain pathologies, and cognition in community-dwelling older adults**

A.S. Buchman, L. Yu, R.S. Wilson, A. Lim, R.J. Dawe, C. Gaiteri, S.E. Leurgans, J.A. Schneider, and D.A. Bennett

[Editorial](#), p. 362 [Podcast](#)

- 371 **Type 2 diabetes mellitus, brain atrophy, and cognitive decline**

C. Moran, R. Beare, W. Wang, M. Callisaya, and V. Srikanth, for the Alzheimer's Disease Neuroimaging Initiative (ADNI)

[Ahead of Print Articles and Editorials](#)

NPub.org/aheadofprint

Continued

372 **Postmortem neurodegenerative markers and trajectories of decline in cognitive systems**

R.S. Wilson, J. Yang, L. Yu, S.E. Leurgans, A.W. Capuano, J.A. Schneider, D.A. Bennett, and P.A. Boyle

373 **Diagnostic accuracy of noncontrast CT imaging markers in cerebral venous thrombosis**

P.-J. Buyck, S.M. Zuurbier, C. Garcia-Esperon, M.A. Barboza, P. Costa, I. Escudero, D. Renard, R. Lemmens, N. Hinteregger, F. Fazekas, J.J. Conde, E. Giralte-Steinhauer, S. Hiltunen, A. Arauz, A. Pezzini, J. Montaner, J. Putaala, C. Weimar, L. Churilov, T. Gattringer, H. Asadi, T. Tatlisumak, J.M. Coutinho, P. Demaerel, and V. Thijs

CME Course Class of Evidence

374 **A large multicenter study of pediatric myotonic dystrophy type 1 for evidence-based management**

E. Lagrue, C. Dogan, M. De Antonio, F. Audic, N. Bach, C. Barnerias, R. Bellance, C. Cances, B. Chabrol, J.-M. Cuisset, I. Desguerre, J. Durigneux, C. Espil, M. Fradin, D. Héron, A. Isapof, A. Jacquin-Piques, H. Journal, C. Laroche-Raynaud, V. Laugel, A. Magot, V. Manel, M. Mayer, Y. Péréon, J. Perrier-Boeswillald, S. Peudenier, S. Quijano-Roy, S. Ragot-Mandry, C. Richelme, F. Rivier, P. Sabouraud, C. Sarret, H. Testard, C. Vanhulle, U. Walthier-Louvier, R. Gherardi, D. Hamroun, and G. Bassez

CME Course

375 **Cardiac and skeletal muscle effects in the randomized HOPE-Duchenne trial**

M. Taylor, J. Jefferies, B. Byrne, J. Lima, B. Ambale-Venkatesh, M.R. Ostovaneh, R. Makkar, B. Goldstein, R.R. Smith, J. Fudge, K. Malliaras, B. Fedor, J. Rudy, J.M. Pogoda, L. Marbán, D.D. Ascheim, E. Marbán, and R.G. Victor

Open Access Article Class of Evidence

What's Happening376 **What's happening in *Neurology*[®] Genetics****Clinical Implications of Neuroscience Research**377 **Autonomic nervous system and neuroimmune interactions: New insights and clinical implications**

E.E. Benarroch

Clinical/Scientific Notes386 **The apnea test in brain death determination using oxygen diffusion method remains safe**

A. Daneshmand, A.A. Rabinstein, and E.F.M. Wijdicks

NeuroImages388 **Shape-similar errors in Chinese pure alexia**

S.-L. Yang, X. Han, and Q. Dong

Resident & Fellow Section390 **Right Brain: Flip to the other side**

D. Garg and K.C. Joshi

e879 **Education Research: An arts-based curriculum for neurology residents**

M.B. Harrison and N. Chiota-McCollum

e884 **Teaching NeuroImages: MRI findings in an infant with cavitating leukoencephalopathy**

A. Hong, P. Assaad, and S. Karkare

e886 **Teaching Video NeuroImages: Horizontal gaze palsy with progressive scoliosis**

H.K. Yang, J.-Y. Choi, K.S. Park, J.H. Kim, and J.-M. Hwang

Video

Global Perspectives391 **Development of a neurology training program in Haiti**

K. Israel, S.M. Strander, S. Pierre, L. Martineau, M.E. Morse, and A.L. Berkowitz

Disputes & Debates: Editors' Choice395 **Editors' note: Outcome after seizure recurrence on antiepileptic drug withdrawal following temporal lobectomy**

A. Lewis and S. Galetta

395 **Reader response: Outcome after seizure recurrence on antiepileptic drug withdrawal following temporal lobectomy**

N.K. Sethi

396 **Author response: Outcome after seizure recurrence on antiepileptic drug withdrawal following temporal lobectomy**

C. Rathore and M.K. Jeyaraj

396 **Editors' note: Incidence of MS has increased markedly over 6 decades in Denmark particularly with late onset and in women**

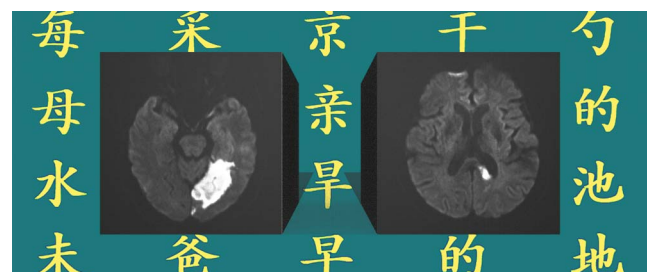
A. Lewis and S. Galetta

397 **Reader response: Incidence of MS has increased markedly over 6 decades in Denmark particularly with late onset and in women**

S.A. Sajedi

397 **Author response: Incidence of MS has increased markedly over 6 decades in Denmark particularly with late onset and in women**

N. Koch-Henriksen

DepartmentIn the Next Issue of *Neurology*[®]

Cover image

Example of shape-similar errors in an oral reading test that involve occipital lobe, temporal lobe, and corpus callosum and reveal right homonymous hemianopsia and Chinese pure alexia. Stylized by Cindy Abair, *Neurology* Senior Graphics Editor.

See page 388

Neurology®

92 (8)

Neurology 2019;92:e866-397

This information is current as of January 1, 2019

Updated Information & Services

including high resolution figures, can be found at:
<http://n.neurology.org/content/92/8.full>

Permissions & Licensing

Information about reproducing this article in parts (figures, tables) or in its entirety can be found online at:
http://www.neurology.org/about/about_the_journal#permissions

Reprints

Information about ordering reprints can be found online:
<http://n.neurology.org/subscribers/advertise>

Neurology® is the official journal of the American Academy of Neurology. Published continuously since 1951, it is now a weekly with 48 issues per year. Copyright . All rights reserved. Print ISSN: 0028-3878. Online ISSN: 1526-632X.

