

Teaching NeuroImages: Diffuse cerebrovascular susceptibility artifact following ferumoxytol infusion

Philip Gastrell, MD, Joseph Carrera, MD, Prem Batchala, MD, and Andrew Southerland, MD

Neurology® 2019;93:e1662-e1663. doi:10.1212/WNL.00000000000008367

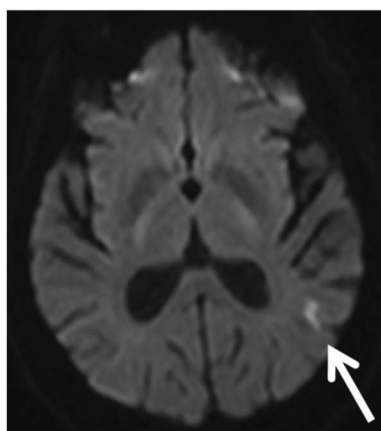
Correspondence

Dr. Gastrell

ptg2d@

hscmail.mcc.virginia.edu

Figure 1 Diffusion-weighted imaging sequence of brain MRI demonstrates left temporoparietal hyperintensity (white arrow) consistent with acute infarction



A 79-year-old woman presented with dysarthria, aphasia, and right hemiparesis. MRI of the brain demonstrated a small acute infarct in the left temporoparietal convexity (figure 1) and a marked decrease in susceptibility signal of the cerebral vasculature (figure 2). Due to her religious beliefs (Jehovah's Witness), the patient's anemia is treated with ferumoxytol infusions rather than red blood cell transfusion. She received an infusion 1 day prior to her scan. Susceptibility artifact of cerebral vasculature following IV iron therapy has been described.¹ Ferumoxytol has gained interest as an MRI contrast agent in patients with decreased renal function.²

MORE ONLINE

→ Teaching slides

links.lww.com/WNL/A981

Author contributions

P. Gastrell: drafting/revising the manuscript, study concept or design, accepts responsibility for conduct of research and final approval. J. Carrera: drafting/revising the manuscript, study concept or design, accepts responsibility for conduct of research and final approval. P. Batchala: drafting/revising the manuscript, data acquisition, study concept or design, analysis or interpretation of data, accepts responsibility for conduct of research and final approval. A. Southerland: drafting/revising the manuscript, data acquisition, study concept or design, accepts responsibility for conduct of research and final approval.

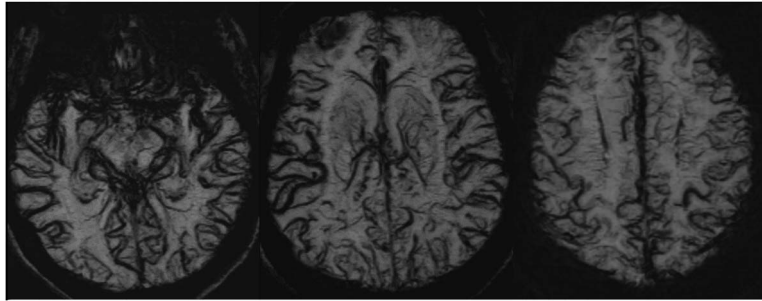
Study funding

No targeted funding reported.

From the Departments of Neurology (P.G., J.C., A.S.) and Radiology (P.B.), University of Virginia, Charlottesville.

Go to Neurology.org/N for full disclosures. Funding information and disclosures deemed relevant by the authors, if any, are provided at the end of the article.

Figure 2 Susceptibility-weighted imaging of brain MRI demonstrates markedly diminished susceptibility signal throughout the cerebrovasculature



Disclosure

The authors report no disclosures relevant to the manuscript.
Go to [Neurology.org/N](https://www.neurology.org/N) for full disclosures.

References

1. Hoque K, Myers C, Law M, Kim P. MRI brain findings of intravenous iron therapy. *Neurographics* 2017;7:61–63.
2. Bashir MR, Bhatti L, Marin D, Nelson RC. Emerging applications for ferumoxytol as a contrast agent in MRI. *J Magn Reson Imaging* 2014;41:884–898.

Neurology®

Teaching NeuroImages: Diffuse cerebrovascular susceptibility artifact following ferumoxytol infusion

Philip Gastrell, Joseph Carrera, Prem Batchala, et al.

Neurology 2019;93:e1662-e1663

DOI 10.1212/WNL.00000000000008367

This information is current as of October 21, 2019

Updated Information & Services	including high resolution figures, can be found at: http://n.neurology.org/content/93/17/e1662.full
References	This article cites 2 articles, 0 of which you can access for free at: http://n.neurology.org/content/93/17/e1662.full#ref-list-1
Subspecialty Collections	This article, along with others on similar topics, appears in the following collection(s): All Cerebrovascular disease/Stroke http://n.neurology.org/cgi/collection/all_cerebrovascular_disease_stroke All Imaging http://n.neurology.org/cgi/collection/all_imaging MRI http://n.neurology.org/cgi/collection/mri
Permissions & Licensing	Information about reproducing this article in parts (figures, tables) or in its entirety can be found online at: http://www.neurology.org/about/about_the_journal#permissions
Reprints	Information about ordering reprints can be found online: http://n.neurology.org/subscribers/advertise

Neurology® is the official journal of the American Academy of Neurology. Published continuously since 1951, it is now a weekly with 48 issues per year. Copyright © 2019 American Academy of Neurology. All rights reserved. Print ISSN: 0028-3878. Online ISSN: 1526-632X.

