

# Teaching NeuroImages: Bilateral optic neuritis

## When to suspect anti-MOG antibodies

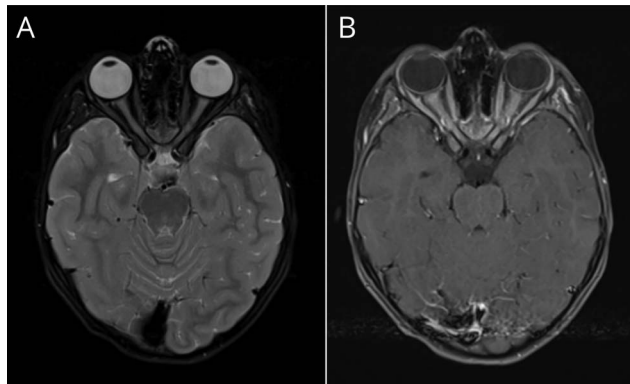
Ana Felipe-Rucián, MD, Andreas Wegener-Panzer, MD, Isabelle Naßenstein, MD, Markus Reindl, MD, PhD, and Kevin Rostásy, MD

*Neurology*® 2020;95:e2045-e2046. doi:10.1212/WNL.0000000000010264

### Correspondence

Dr. Rostásy  
k.rostasy@  
kinderklinik-datteln.de

**Figure** Brain MRI with contrast



Brain MRI shows bilateral and longitudinally extensive optic neuritis with T2 hyperintensity (A) and perineural enhancement (B).

A 6-year-old girl developed sudden onset painless loss of vision with swelling of both optic discs. Brain MRI demonstrated bilateral extensive optic nerve involvement with perineural enhancement (figure). Her vision recovered completely after treatment with IV methylprednisolone.<sup>1</sup> Serum myelin oligodendrocyte glycoprotein (MOG) antibodies tested positive.

The combination of bilateral loss of vision, longitudinal extensive optic neuritis with sparing of the chiasma, perineural enhancement, and disc edema should alert the physician to the diagnosis of bilateral optic neuritis associated with MOG antibodies. These findings are rare in patients with multiple sclerosis or aquaporin-4-positive neuromyelitis optica, thus helping to differentiate these important differential diagnoses.<sup>2</sup>

### Study funding

No targeted funding reported.

### Disclosure

The authors report no disclosures relevant to the manuscript. Go to [Neurology.org/N](https://www.neurology.org/N) for full disclosures.

### MORE ONLINE

→ **Teaching slides**  
[links.lww.com/WNL/B166](https://links.lww.com/WNL/B166)

From the Neurology Section (A.F.-R.), Pediatric Service, Vall d'Hebron Hospital, Barcelona, Spain; Departments of Radiology (A.W.-P., I.N.) and Pediatric Neurology (K.R.), Children's Hospital Datteln, University Witten/Herdecke, Germany; and Division of Pediatric Neurology (M.R.), Department of Pediatrics I, Medical University of Innsbruck, Austria.

Go to [Neurology.org/N](https://www.neurology.org/N) for full disclosures.

---

## Appendix Authors

Name	Location	Contribution
<b>Ana Felipe-Rucián, MD</b>	Vall d'Hebron Hospital Barcelona, Spain	Study concept and design, first draft, literature review
<b>Andreas Wegener-Panzer, MD</b>	Children's Hospital Datteln, University Witten/Herdecke, Germany	Neuroimaging discussion and critical review of manuscript for intellectual content
<b>Isabelle Naßenstein, MD</b>	Children's Hospital Datteln, University Witten/Herdecke, Germany	Neuroimaging discussion
<b>Markus Reindl, MD, PhD</b>	Medical University of Innsbruck, Austria	Review of manuscript for intellectual content
<b>Kevin Rostásy</b>	Children's Hospital Datteln, University Witten/Herdecke, Germany	Study concept and design, first draft, literature review and critical review of manuscript for intellectual content

## References

1. Chen JJ, Bhatti MT. Clinical phenotype, radiological features, and treatment of myelin oligodendrocyte glycoprotein-immunoglobulin G (MOG-IgG) optic neuritis. *Curr Opin Neurol* 2020;33:47–54.
2. Salama S, Khan M, Shanechi A, et al. MRI differences between MOG antibody disease and AQP4 NMOSD. *Mult Scler* 2020:1352458519893093.

# Neurology®

## Teaching NeuroImages: Bilateral optic neuritis: When to suspect anti-MOG antibodies

Ana Felipe-Rucián, Andreas Wegener-Panzer, Isabelle Naßenstein, et al.  
*Neurology* 2020;95:e2045-e2046 Published Online before print July 9, 2020  
DOI 10.1212/WNL.0000000000010264

**This information is current as of July 9, 2020**

<b>Updated Information &amp; Services</b>	including high resolution figures, can be found at: <a href="http://n.neurology.org/content/95/14/e2045.full">http://n.neurology.org/content/95/14/e2045.full</a>
<b>References</b>	This article cites 1 articles, 0 of which you can access for free at: <a href="http://n.neurology.org/content/95/14/e2045.full#ref-list-1">http://n.neurology.org/content/95/14/e2045.full#ref-list-1</a>
<b>Subspecialty Collections</b>	This article, along with others on similar topics, appears in the following collection(s): <b>All Demyelinating disease (CNS)</b> <a href="http://n.neurology.org/cgi/collection/all_demyelinating_disease_cns">http://n.neurology.org/cgi/collection/all_demyelinating_disease_cns</a> <b>All Pediatric MRI</b> <a href="http://n.neurology.org/cgi/collection/all_pediatric_mri">http://n.neurology.org/cgi/collection/all_pediatric_mri</a> <b>Optic neuritis; see Neuro-ophthalmology/Optic Nerve</b> <a href="http://n.neurology.org/cgi/collection/optic_neuritis">http://n.neurology.org/cgi/collection/optic_neuritis</a>
<b>Permissions &amp; Licensing</b>	Information about reproducing this article in parts (figures, tables) or in its entirety can be found online at: <a href="http://www.neurology.org/about/about_the_journal#permissions">http://www.neurology.org/about/about_the_journal#permissions</a>
<b>Reprints</b>	Information about ordering reprints can be found online: <a href="http://n.neurology.org/subscribers/advertise">http://n.neurology.org/subscribers/advertise</a>

*Neurology*® is the official journal of the American Academy of Neurology. Published continuously since 1951, it is now a weekly with 48 issues per year. Copyright © 2020 American Academy of Neurology. All rights reserved. Print ISSN: 0028-3878. Online ISSN: 1526-632X.

