

Teaching Video NeuroImages: Wilson Disease Presenting With Catatonia

Roshni Abee Patel, MD, and Meagan Bailey, MD, MS

Neurology® 2021;96:e2781-e2782. doi:10.1212/WNL.00000000000012038

Correspondence

Dr. Patel
roshnipatel1988@gmail.com

A 29-year-old man with a history of depression on fluoxetine presented with 4 months of progressive abdominal pain and hypoactive encephalopathy. On examination, he was non-responsive, bradykinetic, spastic, and had catatonia with waxy flexibility (video 1). Bush-Francis Catatonia Rating Scale score was 28 (table). He had new liver cirrhosis; serum ceruloplasmin was low and 24-hour urine copper was elevated. MRI revealed abnormal signal in basal ganglia and pons (figure). Two heterozygous mutations in the *ATP7B* gene (c.1934T > G and c.207 G > T) confirmed the diagnosis of Wilson disease. Zinc and penicillamine were initiated for copper reduction; catatonia did not respond to benzodiazepines. He was discharged home but required full care from family (nonambulatory, required help with all activities of daily living), and neurologic status was unchanged 3 months after discharge. Catatonia is a rare and underappreciated manifestation in Wilson disease¹; early recognition is essential for prompt initiation of chelation therapy.²

Study Funding

No targeted funding reported.

Disclosure

The authors report no disclosures relevant to the manuscript. Go to Neurology.org/N for full disclosures.

MORE ONLINE

→ Teaching slides

<http://links.lww.com/WNL/B368>

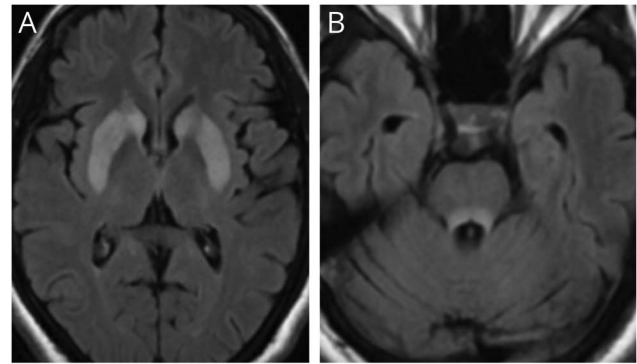
▶ Video

Table Bush-Francis Catatonia Rating Scale With Subscores

Signs and symptoms	Patient score ^a
Excitement	0
Immobility/stupor	2
Mutism	3
Staring	3
Posturing/cataplexy	3
Grimacing	3
Echopraxia/echolalia	0
Stereotypy	0
Mannerisms	0
Verbigeration	1
Rigidity	2
Negativism	0
Waxy flexibility	3
Withdrawal	2
Impulsivity	0
Automatic obedience	1
Mitgehen	0
Gegenhalten	0
Ambitendency	3
Grasp reflex	0
Perseveration	3
Combativeness	1
Autonomic abnormality	1
Total score	28

^a All items are rated on scale of 0–3.

Figure MRI Fluid-Attenuated Inversion Recovery



Hyperintensities seen in bilateral caudate and lentiform nuclei (A) and dorsal pons (B).

Appendix Authors

Name	Location	Contribution
Roshni Patel, MD	Rush University Medical Center, Chicago, IL	Designed and conceptualized study, major role in acquisition of data, drafted the manuscript for intellectual content
Meagan Bailey, MD, MS	Rush University Medical Center, Chicago, IL	Revised the manuscript for intellectual content

References

1. Basu A, Thanapal S, Sood M, Khandelwal SK. Catatonia: an unusual manifestation of Wilson's disease. *J Neuropsychiatry Clin Neurosci*. 2015;27:72-73.
2. Bandmann O, Weiss KH, Kaler SG. Wilson's disease and other neurological copper disorders. *Lancet Neurol*. 2015;14:103-113.

Neurology[®]

Teaching Video NeuroImages: Wilson Disease Presenting With Catatonia
Roshni Abee Patel and Meagan Bailey
Neurology 2021;96:e2781-e2782 Published Online before print April 14, 2021
DOI 10.1212/WNL.0000000000012038

This information is current as of April 14, 2021

Updated Information & Services	including high resolution figures, can be found at: http://n.neurology.org/content/96/22/e2781.full
References	This article cites 2 articles, 0 of which you can access for free at: http://n.neurology.org/content/96/22/e2781.full#ref-list-1
Subspecialty Collections	This article, along with others on similar topics, appears in the following collection(s): All Genetics http://n.neurology.org/cgi/collection/all_genetics All Psychiatric disorders http://n.neurology.org/cgi/collection/all_psychiatric_disorders Metabolic disease (inherited) http://n.neurology.org/cgi/collection/metabolic_disease_inherited MRI http://n.neurology.org/cgi/collection/mri Parkinson's disease/Parkinsonism http://n.neurology.org/cgi/collection/parkinsons_disease_parkinsonism
Permissions & Licensing	Information about reproducing this article in parts (figures, tables) or in its entirety can be found online at: http://www.neurology.org/about/about_the_journal#permissions
Reprints	Information about ordering reprints can be found online: http://n.neurology.org/subscribers/advertise

Neurology® is the official journal of the American Academy of Neurology. Published continuously since 1951, it is now a weekly with 48 issues per year. Copyright © 2021 American Academy of Neurology. All rights reserved. Print ISSN: 0028-3878. Online ISSN: 1526-632X.

