

Teaching NeuroImage: Cerebral Amyloid Angiopathy–Related Inflammation

An Interesting Evolution of Imaging Findings

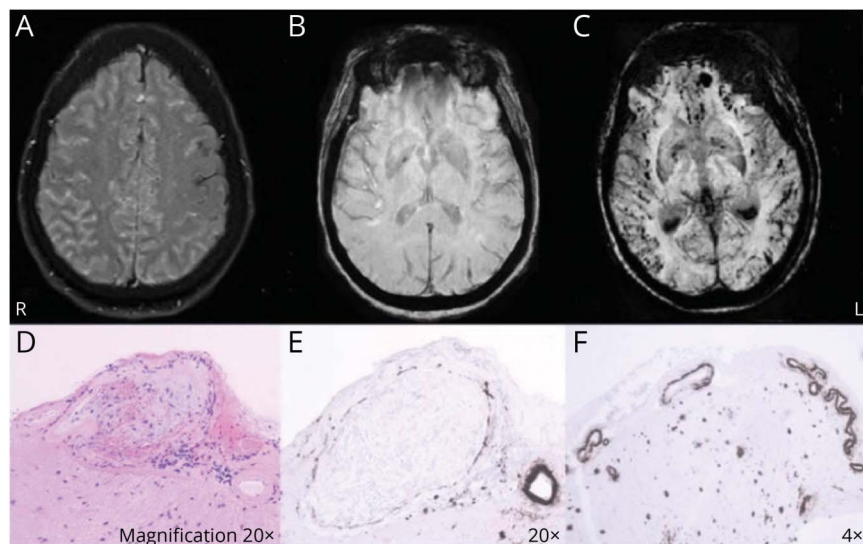
Alex Dudley, MB BCH, BAO, Kieron Sweeney, MB BCH, BAO, MD, FRCSI (SN),
Seamus Looby, MB BCH, BAO, FRCPI, FFR RCSI, Michael Farrell, FRCPI, FRCPath, FRCPC, and
Eavan McGovern, MB BCH, BAO, PhD

Neurology® 2022;99:216-217. doi:10.1212/WNL.0000000000200833

Correspondence

Dr. Dudley
alexander.dudley@
ucdconnect.ie

Figure MRI and Histology



(A) Fluid-attenuated inversion recovery sequence shows extensive sulcal hyperintensity. (B) Normal SWI MIP. (C) SWI MIP shows multiple peripheral microhaemorrhages. (D) Aneurysmal meningeal vessel, occluded by recanalising thrombus with extensive perivascular lymphocytic infiltration. (E) Parallel section of cortex with meninges, brown staining indicates accumulated beta-A4. (F) Meningeal and parenchymal vascular beta-A4 immunoreactivity. Plaques also evident. MIP = minimum intensity projection; SWI = susceptibility-weighted imaging.

A 77-year-old previously well woman presented with confusion, visual hallucinations, and signs of parietal lobe dysfunction, preceded by 5 days of headache. MRI of the brain demonstrated diffuse sulcal fluid-attenuated inversion recovery hyperintensities (Figure, A) and subtle leptomeningeal enhancement. Susceptibility-weighted imaging (SWI) was normal (Figure, B). Neurosurgical biopsy-confirmed cerebral amyloid angiopathy with perivascular inflammation (Figure, D–F). Pulsed methylprednisolone was given with excellent clinical response. MRI 7 weeks post symptom onset demonstrated widespread microhaemorrhages (Figure, C).

In the largest prospective study, all patients had abnormal SWI at presentation.¹ Normal SWI at presentation can rarely occur in CAA-ri; therefore, clinical suspicion is important.²

MORE ONLINE

Teaching slides

links.lww.com/WNL/C81

From the Departments of Neurology (A.D., E.M.), Radiology (S.L.), and Neuropathology (M.F.), and National Centre for Neurosurgery (K.S.), Beaumont Hospital, and Royal College of Surgeons in Ireland (K.S., E.M.), Dublin.

Go to Neurology.org/N for full disclosures. Funding information and disclosures deemed relevant by the authors, if any, are provided at the end of the article.

Study Funding

No targeted funding reported.

Disclosure

The authors report no disclosures relevant to the manuscript. Go to [Neurology.org/N](https://www.neurology.org/N) for full disclosures.

Publication History

Received by *Neurology* January 7, 2022. Accepted in final form April 22, 2022. Submitted and externally peer reviewed. The handling editor was Roy Strowd III, MD, MEd, MS.

Appendix Authors

Name	Location	Contribution
Alex Dudley, MB BCh, BAO	Department of Neurology, Beaumont Hospital, Dublin, Ireland	Drafting/revision of the manuscript for content, including medical writing for content; major role in the acquisition of data; study concept or design
Kieron Sweeney, MB BCh, BAO, MD, FRCSI (SN)	National Centre for Neurosurgery, Beaumont Hospital; Royal College of Surgeons in Ireland, Dublin	Major role in the acquisition of data

Appendix (continued)

Name	Location	Contribution
Seamus Looby, MB BCh, BAO, FRCP, FFR RCSI	Department of Radiology, Beaumont Hospital, Dublin, Ireland	Drafting/revision of the manuscript for content, including medical writing for content; study concept or design; analysis or interpretation of data
Michael Farrell, FRCP, FRCPPath, FRCPC	Department of Neuropathology, Beaumont Hospital, Dublin, Ireland	Drafting/revision of the manuscript for content, including medical writing for content; analysis or interpretation of data
Eavan McGovern, MB BCh, BAO, PhD	Department of Neurology, Beaumont Hospital; Royal College of Surgeons in Ireland, Dublin	Drafting/revision of the manuscript for content, including medical writing for content; major role in the acquisition of data; study concept or design; analysis or interpretation of data

References

1. Antolini L, DiFrancesco JC, Zedde M, et al. Spontaneous ARIA-like events in cerebral amyloid angiopathy-related inflammation: a multicenter prospective longitudinal cohort study. *Neurology*. 2021;97(18):e1809-e1822.
2. Aghetti A, Sène D, Polivka M, et al. Cerebral amyloid angiopathy related inflammation with prominent meningeal involvement. A report of 2 cases. *Front Neurol*. 2019;10:984.



Without Borders – A curated collection featuring advances in global neurology

This *Neurology*[®] special interest website is the go-to source for tracking science and politics of neurology beyond the United States, featuring up-to-the-minute blogs, scholarly perspectives, and academic review of developments and research from *Neurology* journals and other sources.

Expand your world view at [Neurology.org/woborders](https://www.neurology.org/woborders).

Neurology®

Teaching NeuroImage: Cerebral Amyloid Angiopathy–Related Inflammation: An Interesting Evolution of Imaging Findings

Alex Dudley, Kieron Sweeney, Seamus Looby, et al.
Neurology 2022;99;216-217 Published Online before print June 2, 2022
DOI 10.1212/WNL.0000000000200833

This information is current as of June 2, 2022

Updated Information & Services	including high resolution figures, can be found at: http://n.neurology.org/content/99/5/216.full
References	This article cites 2 articles, 1 of which you can access for free at: http://n.neurology.org/content/99/5/216.full#ref-list-1
Subspecialty Collections	This article, along with others on similar topics, appears in the following collection(s): All Cerebrovascular disease/Stroke http://n.neurology.org/cgi/collection/all_cerebrovascular_disease_stroke All Cognitive Disorders/Dementia http://n.neurology.org/cgi/collection/all_cognitive_disorders_dementia Hallucinations http://n.neurology.org/cgi/collection/hallucinations MRI http://n.neurology.org/cgi/collection/mri
Permissions & Licensing	Information about reproducing this article in parts (figures,tables) or in its entirety can be found online at: http://www.neurology.org/about/about_the_journal#permissions
Reprints	Information about ordering reprints can be found online: http://n.neurology.org/subscribers/advertise

Neurology® is the official journal of the American Academy of Neurology. Published continuously since 1951, it is now a weekly with 48 issues per year. Copyright © 2022 American Academy of Neurology. All rights reserved. Print ISSN: 0028-3878. Online ISSN: 1526-632X.

