

Teaching Video NeuroImage: Bilateral Hemifacial Spasm in Giant Cell Arteritis

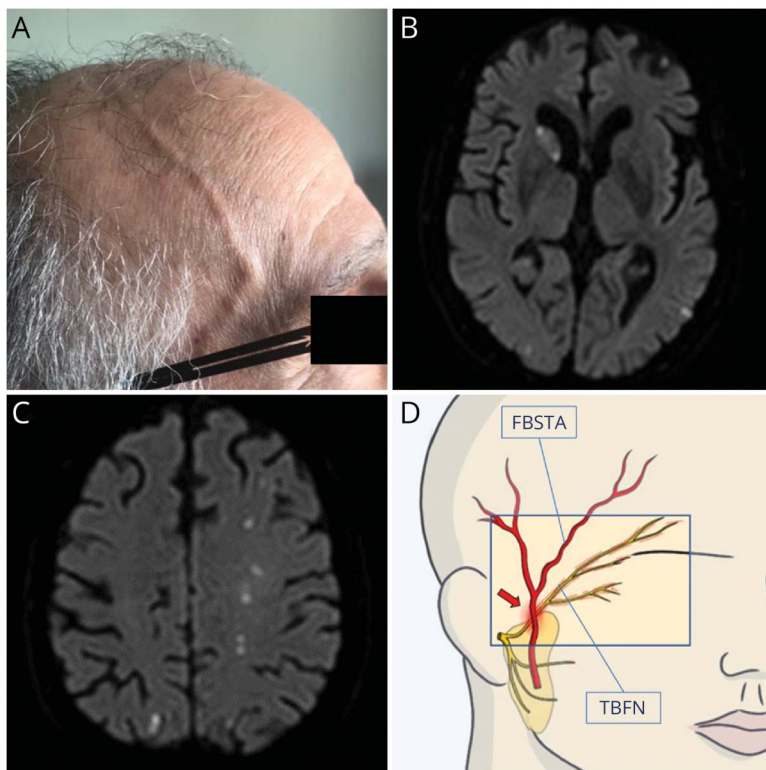
Elia Sechi, MD, Emmanuel Gallus, MD, Paolo Solla, MD, PhD, Daniele Puggioni, MD, Antonio M. Amadu, MD, Renato Ortu, MD, Marco Piras, MD, Giovanni Defazio, MD, PhD, and Gian Luca Erre, MD, PhD

Correspondence

Prof. Solla
paolo.solla@aousassari.it

Neurology® 2022;99:256-257. doi:10.1212/WNL.0000000000200837

Figure Clinical MRI Features Accompanying the Arteritis With Bilateral Hemifacial Spasm



(A) Prominent right temporal artery. (B and C) Brain MRI DWI images showing multiple infarcts. (D) Pathophysiologic hypothesis: TBFN passes in the same anatomical region as the FBSTA and is sometimes injured in temporal artery biopsies (not performed in our patient). Temporal artery inflammation may cause TBFN irritation and hemifacial spasm predominantly involving the upper facial muscles. DWI = diffusion-weighted image; FBSTA = frontal branch of the superficial temporal artery; TBFN = temporal branch of the facial nerve.

An 80-year-old man developed bitemporal headache and scalp tenderness. Both temporal arteries were prominent (Figure, A), with halo sign on ultrasonography.¹ Temporal arteritis was diagnosed and oral prednisone (50 mg/d) initiated. Three days later, he developed spasms of the orbicularis oculi and frontalis muscles with eyebrow elevation and eye twitching (other Babinski sign),² consistent with bilateral hemifacial spasm (Video 1). Brain MRI and time-of-flight angiography revealed exclusively supratentorial acute infarcts (Figure, B and C) without intracranial neurovascular conflicts. Intravenous methylprednisolone (1 g/d for 5 days) was started with resolution of spasms within 24 hours and clinical stabilization. Temporal artery inflammation may cause facial nerve irritation and hemifacial spasm (Figure, D).

MORE ONLINE

Teaching slides

links.lww.com/WNL/C101

▶ Video

From the University of Sassari (E.S., E.G., P.S., D.P., A.M.A., R.O., M.P., G.L.E.); and University of Cagliari (G.D.), Italy.

Go to Neurology.org/N for full disclosures. Funding information and disclosures deemed relevant by the authors, if any, are provided at the end of the article.

Acknowledgment

The authors thank the patient for consenting to the use of his medical records, video, and pictures for this report.

Study Funding

No targeted funding reported.

Disclosure

The authors report no disclosures relevant to the manuscript. Go to [Neurology.org/N](https://www.neurology.org/N) for full disclosures.

Publication History

Received by *Neurology* November 12, 2021. Accepted in final form April 22, 2022. Submitted and externally peer reviewed. The handling editor was Roy Strowd III, MD, MEd, MS.

Appendix Authors

Name	Location	Contribution
Elia Sechi, MD	University of Sassari, Italy	Drafting/revision of the article for content, including medical writing for content; major role in the acquisition of data; study concept or design; and analysis or interpretation of data
Emmanuel Gallus, MD	University of Sassari, Italy	Major role in the acquisition of data; analysis or interpretation of data

Appendix (continued)

Name	Location	Contribution
Paolo Solla, MD, PhD	University of Sassari, Italy	Major role in the acquisition of data; study concept or design; analysis or interpretation of data
Daniele Puggioni, MD	University of Sassari, Italy	Major role in the acquisition of data; analysis or interpretation of data
Antonio M. Amadu, MD	University of Sassari, Italy	Major role in the acquisition of data; analysis or interpretation of data
Renato Ortu, MD	University of Sassari, Italy	Major role in the acquisition of data; analysis or interpretation of data
Marco Piras, MD	University of Sassari, Italy	Major role in the acquisition of data; analysis or interpretation of data
Giovanni Defazio, MD, PhD	University of Cagliari, Italy	Major role in the acquisition of data; study concept or design; analysis or interpretation of data
Gian Luca Erre, MD, PhD	University of Sassari, Italy	Major role in the acquisition of data; study concept or design; analysis or interpretation of data

References

1. Berti A, Casal Moura M, Sechi E, et al. Beyond giant cell arteritis and Takayasu's arteritis: secondary large vessel vasculitis and vasculitis mimickers. *Curr Rheumatol Rep.* 2020;22(12):88.
2. Stamey W, Jankovic J. The other Babinski sign in hemifacial spasm. *Neurology.* 2007; 69(4):402-404.



Without Borders – A curated collection featuring advances in global neurology

This *Neurology*[®] special interest website is the go-to source for tracking science and politics of neurology beyond the United States, featuring up-to-the-minute blogs, scholarly perspectives, and academic review of developments and research from *Neurology* journals and other sources.

Expand your world view at [Neurology.org/woborders](https://www.neurology.org/woborders).

Neurology[®]

Teaching Video NeuroImage: Bilateral Hemifacial Spasm in Giant Cell Arteritis

Elia Sechi, Emmanuel Gallus, Paolo Solla, et al.

Neurology 2022;99:256-257 Published Online before print June 3, 2022

DOI 10.1212/WNL.0000000000200837

This information is current as of June 3, 2022

Updated Information & Services	including high resolution figures, can be found at: http://n.neurology.org/content/99/6/256.full
References	This article cites 2 articles, 1 of which you can access for free at: http://n.neurology.org/content/99/6/256.full#ref-list-1
Citations	This article has been cited by 2 HighWire-hosted articles: http://n.neurology.org/content/99/6/256.full##otherarticles
Subspecialty Collections	This article, along with others on similar topics, appears in the following collection(s): Autoimmune diseases http://n.neurology.org/cgi/collection/autoimmune_diseases Blepharospasm http://n.neurology.org/cgi/collection/blepharospasm Vasculitis http://n.neurology.org/cgi/collection/vasculitis
Permissions & Licensing	Information about reproducing this article in parts (figures, tables) or in its entirety can be found online at: http://www.neurology.org/about/about_the_journal#permissions
Reprints	Information about ordering reprints can be found online: http://n.neurology.org/subscribers/advertise

Neurology® is the official journal of the American Academy of Neurology. Published continuously since 1951, it is now a weekly with 48 issues per year. Copyright © 2022 American Academy of Neurology. All rights reserved. Print ISSN: 0028-3878. Online ISSN: 1526-632X.

