

Neurology®

The most widely read and highly cited peer-reviewed neurology journal
The Official Journal of the American Academy of Neurology



Neurology Publish Ahead of Print

DOI: 10.1212/WNL.000000000201706

Teaching Video NeuroImage: Wernekink Commissure Syndrome

Author(s):

Takashi Nakamura, MD¹; Tatsuya Ueno, M.D.¹; Rie Haga, M.D.¹; Akira Arai, M.D.¹; Masayuki Baba, M.D.¹; Masahiko Tomiyama, MD, PhD²

Corresponding Author:

Takashi Nakamura, t.nakamura@hirosaki-u.ac.jp

Affiliation Information for All Authors: 1. Department of Neurology, Aomori Prefectural Central Hospital, Aomori; 2. Department of Neurology, Institute of Brain Science, Hirosaki University Graduate School of Medicine, Hirosaki.

Equal Author Contribution:

Neurology® Published Ahead of Print articles have been peer reviewed and accepted for publication. This

manuscript will be published in its final form after copyediting, page composition, and review of proofs.

Errors that could affect the content may be corrected during these processes. Videos, if applicable, will be

available when the article is published in its final form.

Contributions:

Takashi Nakamura: Drafting/revision of the manuscript for content, including medical writing for content; Study concept or design

Tatsuya Ueno: Drafting/revision of the manuscript for content, including medical writing for content; Study concept or design

Rie Haga: Drafting/revision of the manuscript for content, including medical writing for content

Akira Arai: Drafting/revision of the manuscript for content, including medical writing for content

Masayuki Baba: Drafting/revision of the manuscript for content, including medical writing for content

Masahiko Tomiyama: Drafting/revision of the manuscript for content, including medical writing for content

Figure Count:

1

Table Count:

0

Search Terms:

[2] All Cerebrovascular disease/Stroke, [6] Infarction, [13] Other cerebrovascular disease/ Stroke, [14] All Clinical Neurology, [120] MRI

Acknowledgment:

We thank Edanz (<https://jp.edanz.com/ac>) for editing a draft of this manuscript.

Study Funding:

The authors report no targeted funding

Disclosures:

The authors report no disclosures relevant to the manuscript.

Preprint DOI:**Received Date:**

2022-06-26

Accepted Date:

2022-11-03

Handling Editor Statement:

Submitted and externally peer reviewed. The handling editor was Whitley Aamodt, MD, MPH.

A 62-year-old woman presented with sudden onset staggering gait and dysarthria.

Neurological examination revealed truncal and appendicular ataxia in all limbs and cerebellar dysarthria (Video 1), slight slowing of internal right eye rotation during leftward gaze, and left eye nystagmus on abduction. The deep tendon reflexes was normal. Diffusion-weighted imaging showed a high-signal midline lesion in the right midbrain (Figure). We diagnosed the patient with Wernekink commissure syndrome caused by midbrain infarction. Wernekink commissure syndrome is a rare syndrome of bilateral ataxia and oculomotor dysfunction caused by caudal paramedian midbrain lesions.^{1,2} The responsible vessel is considered the inferior paramedian mesencephalic artery, which originates from both the distal basilar artery and proximal posterior cerebral artery or the superior cerebellar artery.² This lesion involves the superior cerebellar peduncles, their decussation, and the medial longitudinal fasciculi.² Clinicians should consider midbrain lesions in patients with acute onset bilateral cerebral ataxia.

<http://links.lww.com/WNL/C532>

<http://links.lww.com/WNL/C533>

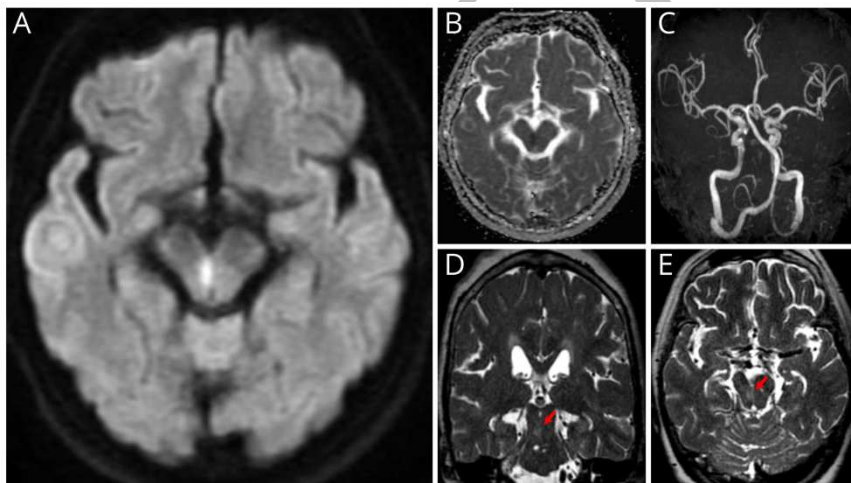
References

1. Dong M, Wang L, Teng W, et al. Wernekink commissure syndrome secondary to a rare 'V'-shaped pure midbrain infarction: a case report and review of the literature. *Int J Neurosci* 2020;130:826-833.
2. Zhou C, Xu Z, Huang B, et al. Caudal paramedian midbrain infarction: a clinical study of imaging, clinical features and stroke mechanisms. *Acta Neurol Belg* 2021;121:443-450.

Figure legend

Figure Brain MRI

(A, B) Axial brain MRI showed hyperintensity and hypointensity in the right paramedian midbrain on diffusion-weighted imaging and apparent diffusion coefficient map, respectively. (C) Magnetic resonance angiography showed no obvious major artery stenosis on day 1. (D, E) Axial and coronal T2-weighted images on day 27 showed a faint high signal lesion at the same site (arrow). The inferior olivary nucleus showed no signal change.



Video 1. Neurological examination showed cerebellar dysarthria, bilateral limb ataxia, and ataxic gait.

Neurology[®]

Teaching Video NeuroImage: Wernekink Commissure Syndrome

Takashi Nakamura, Tatsuya Ueno, Rie Haga, et al.

Neurology published online December 19, 2022

DOI 10.1212/WNL.0000000000201706

This information is current as of December 19, 2022

Updated Information & Services	including high resolution figures, can be found at: http://n.neurology.org/content/early/2022/12/19/WNL.0000000000201706.citation.full
Subspecialty Collections	This article, along with others on similar topics, appears in the following collection(s): All Cerebrovascular disease/Stroke http://n.neurology.org/cgi/collection/all_cerebrovascular_disease_stroke All Clinical Neurology http://n.neurology.org/cgi/collection/all_clinical_neurology Infarction http://n.neurology.org/cgi/collection/infarction MRI http://n.neurology.org/cgi/collection/mri Other cerebrovascular disease/ Stroke http://n.neurology.org/cgi/collection/other_cerebrovascular_disease__stroke
Permissions & Licensing	Information about reproducing this article in parts (figures, tables) or in its entirety can be found online at: http://www.neurology.org/about/about_the_journal#permissions
Reprints	Information about ordering reprints can be found online: http://n.neurology.org/subscribers/advertise

Neurology® is the official journal of the American Academy of Neurology. Published continuously since 1951, it is now a weekly with 48 issues per year. Copyright © 2022 American Academy of Neurology. All rights reserved. Print ISSN: 0028-3878. Online ISSN: 1526-632X.

